

Recent Advances in Gastrointestinal Endoscopy

Sammy Ho, MD

Director of Pancreaticobiliary Services and
Endoscopic Ultrasound

Director of Advanced Endoscopy Fellowship
Montefiore Medical Center

Objectives

- Video cholangioscopy
- EUS-guided pseudocyst drainage and necrosectomy
- EUS-guided biliary access

History of Choledochoscopy

- Introduced in the mid 70s
- Technology not widely used because of
 - Expensive and delicate cholangioscopes
 - Suboptimal image quality
 - Requires 2 operators

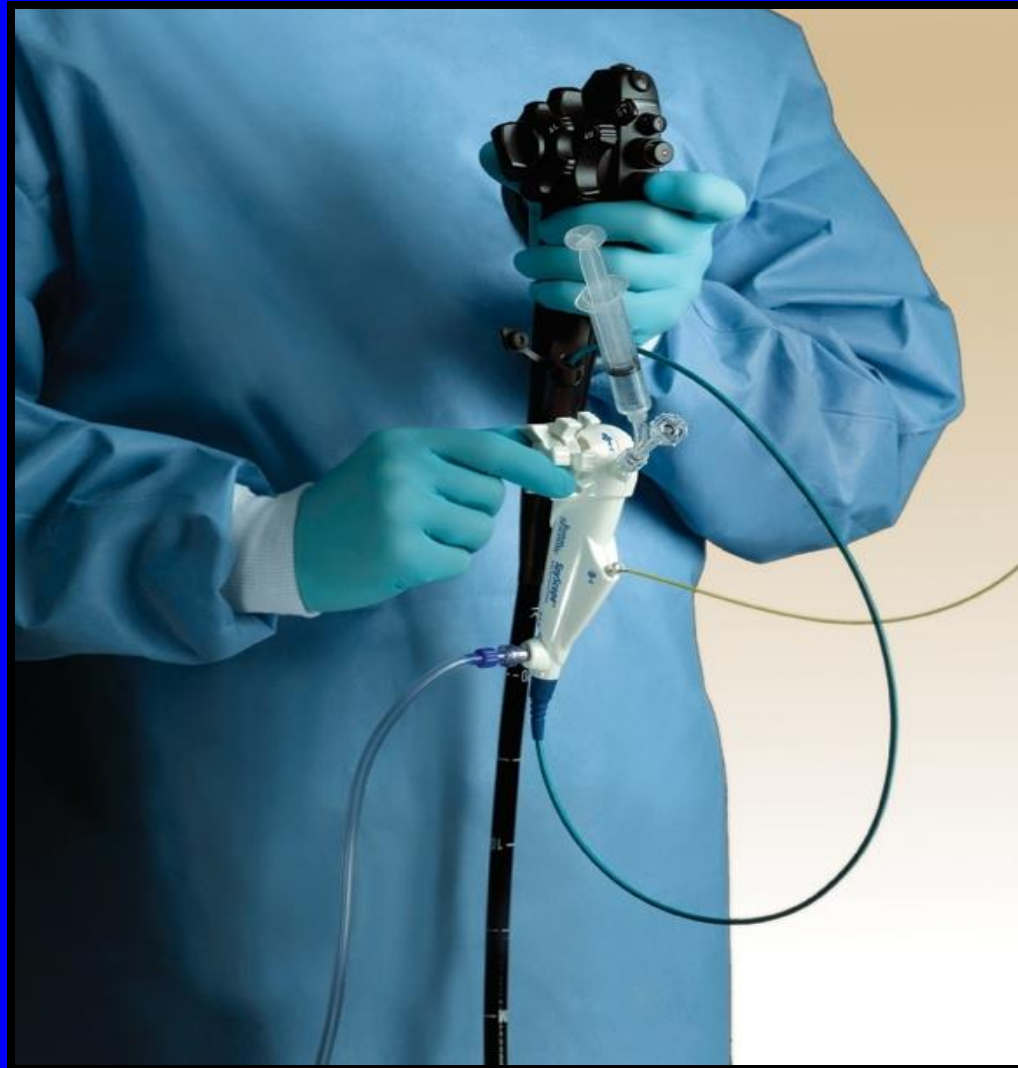

Current Technology: SpyGlass Direct Visualization System

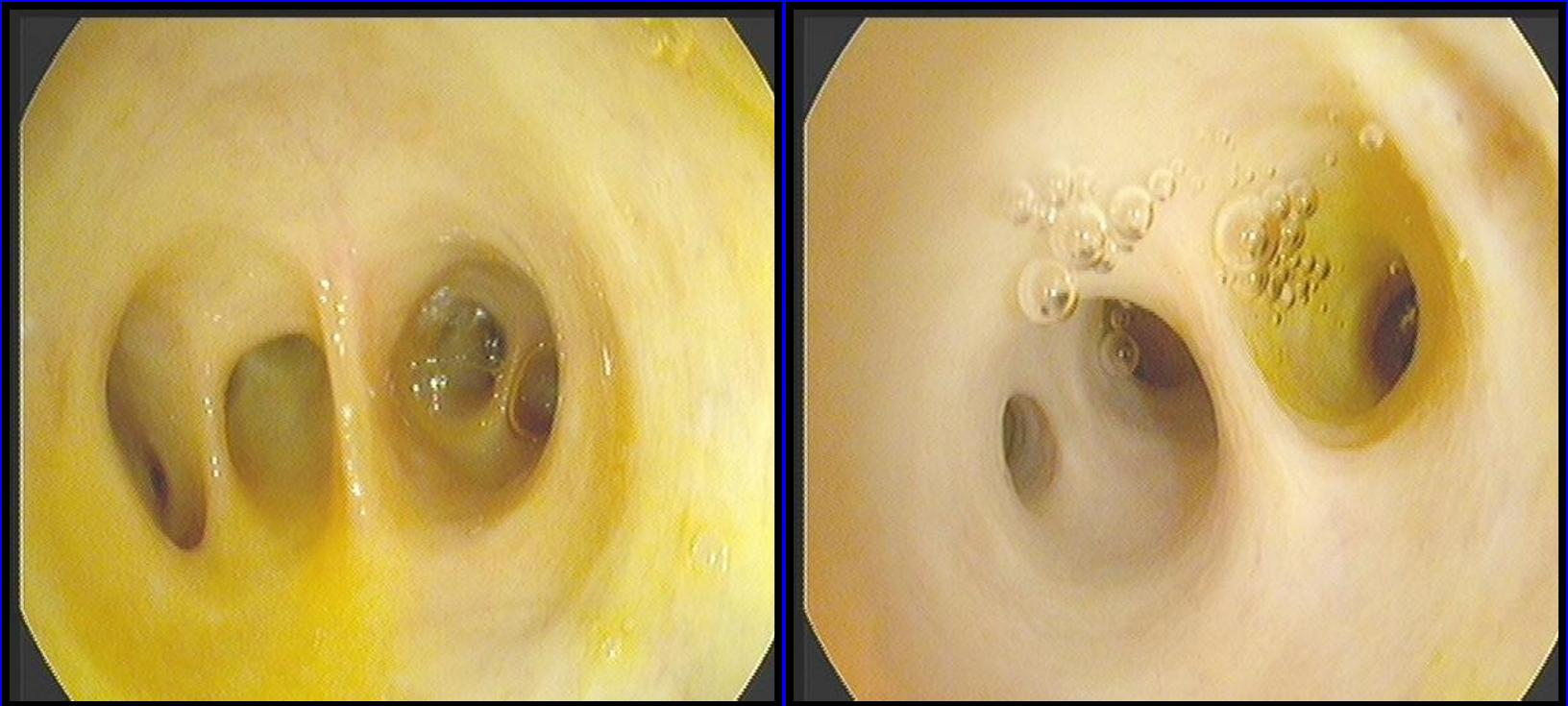
- Single-operator system
- Four-way steering capability
- Dedicated irrigation channels



Single-operator System



Normal Cholangioscopy



Diagnostic Applications

- Bile duct strictures
benign vs. malignant
- Filling defects
tumor vs. stone
- Confirmation of ductal clearance
- Staging for cholangiocarcinoma

Therapeutic Applications

- Direct tissue sampling
- Stone fragmentation
 - electrohydraulic lithotripsy (EHL)
 - laser

Diagnostic accuracy of conventional and cholangioscopy-guided sampling of indeterminate biliary lesions at the time of ERCP: a prospective, long-term follow-up study

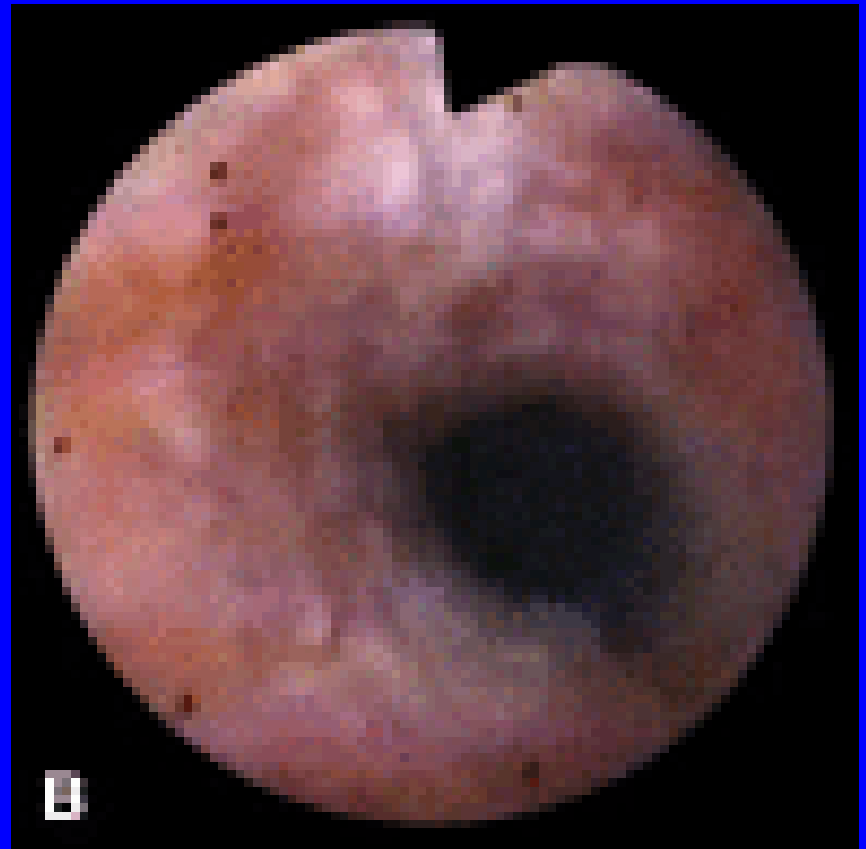
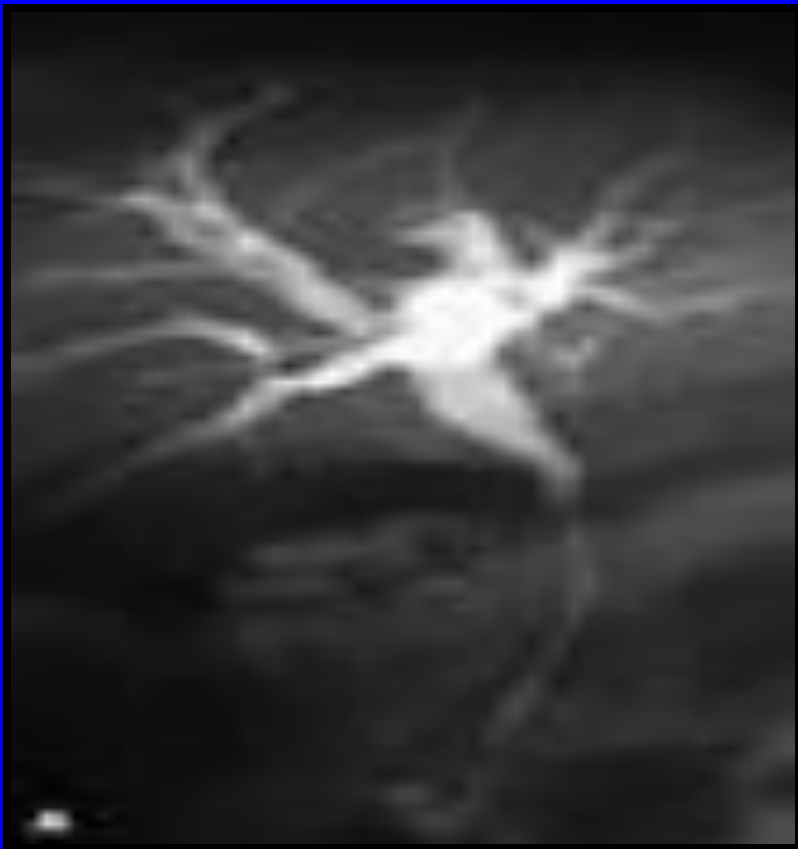
Peter V. Draganov, MD,¹ Shailendra Chauhan, MD,¹ Mihir S. Wagh, MD,¹ Anand R. Gupte, MD,¹ Tong Lin, BS,² Wei Hou, PhD,³ Chris E. Forsmark, MD¹

Gainesville, Florida, USA

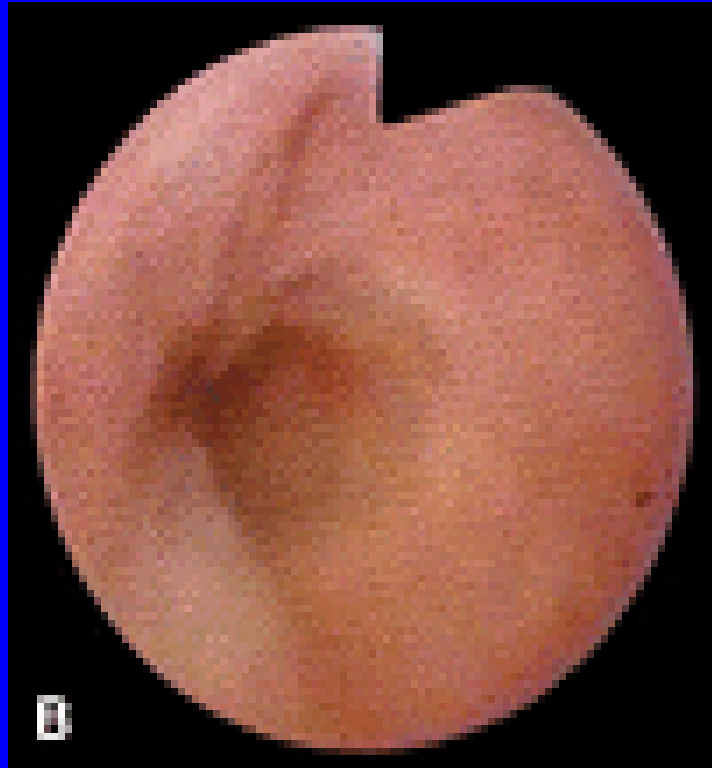
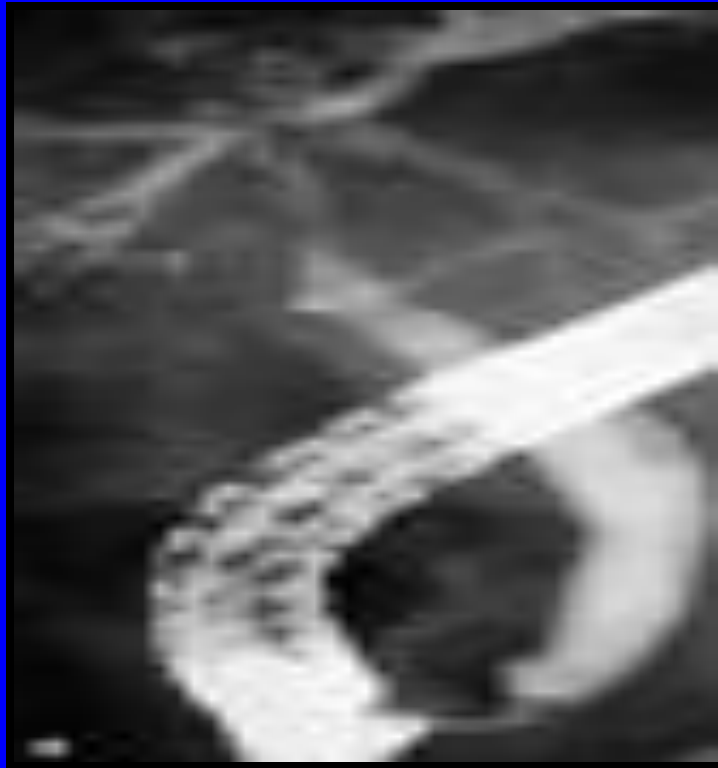
- 26 patients with indeterminate biliary strictures

	Sensitivity	Specificity	NPV
Cytology brush	5.8%	100%	36%
Standard forceps biopsy	29.4%	100%	43%
Cholangioscopic biopsy	76.5%	100%	70%

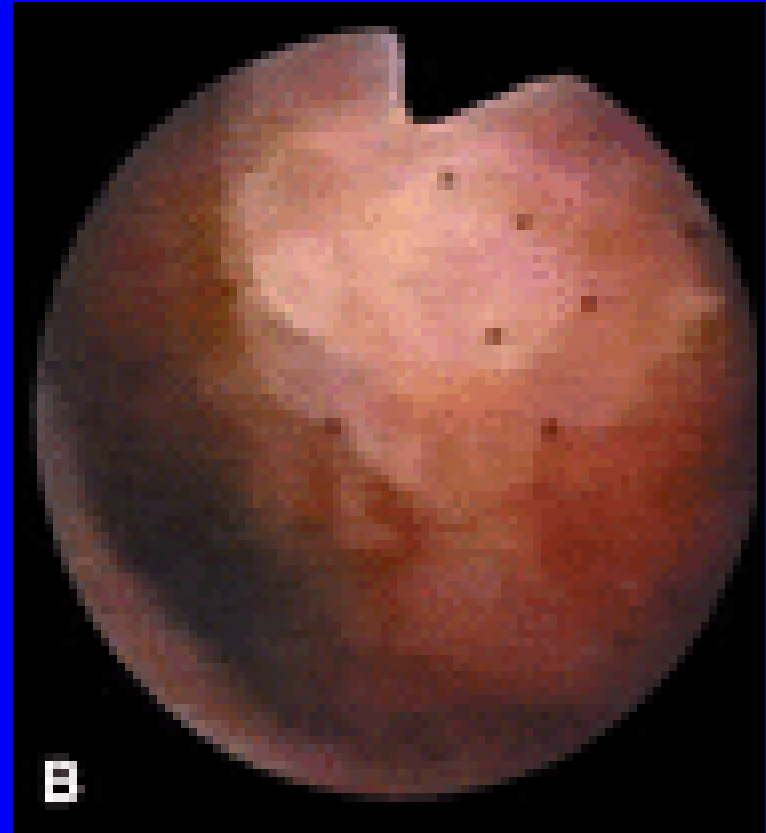
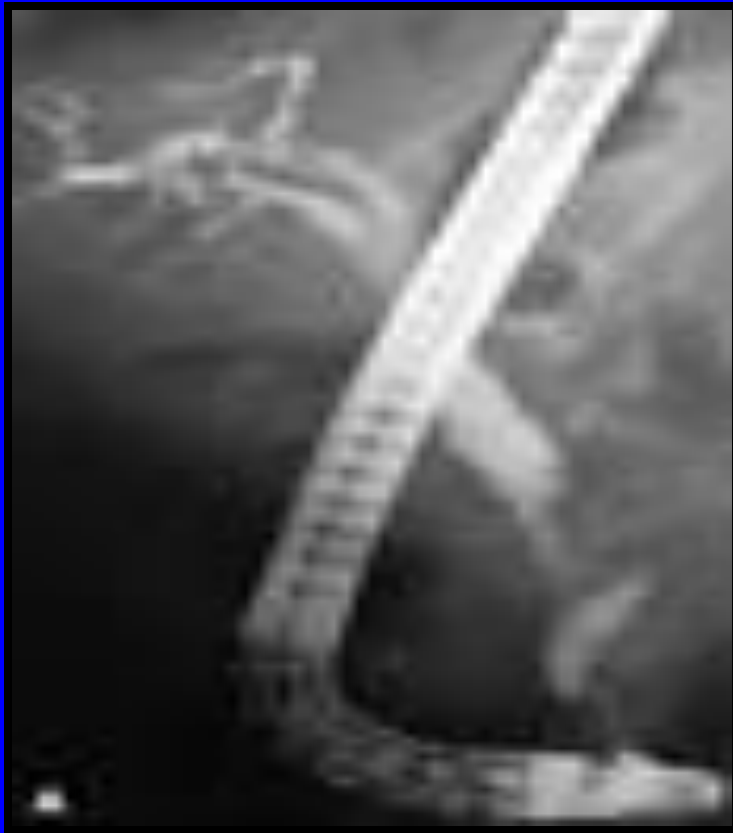Malignant Stricture



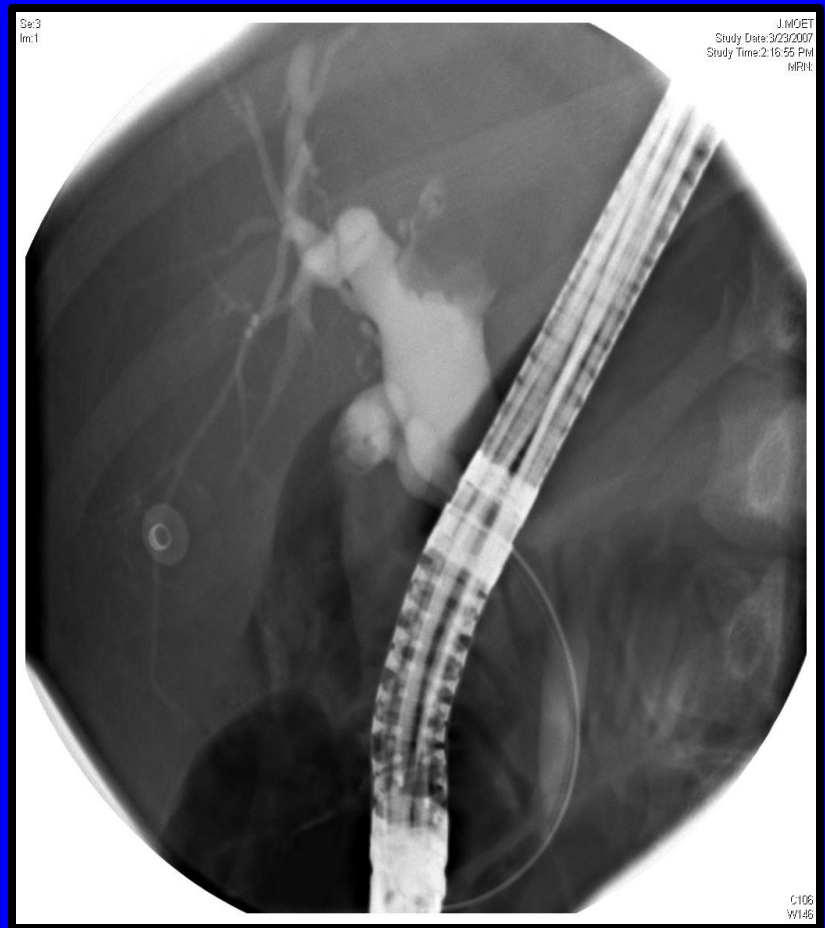
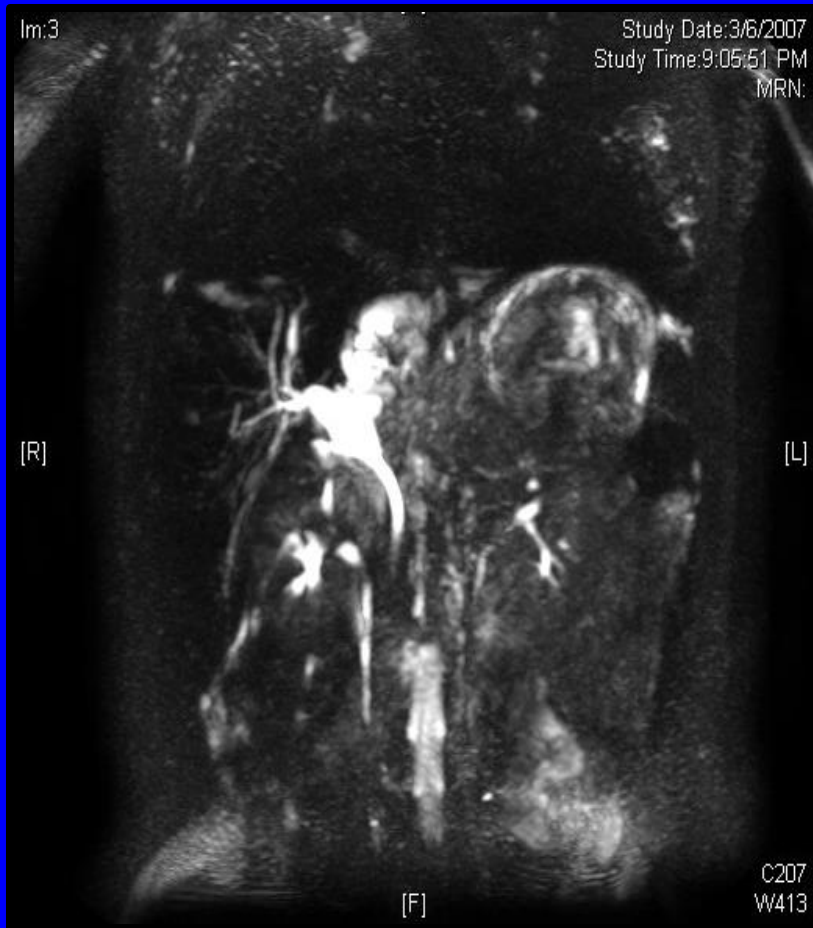Benign Stricture

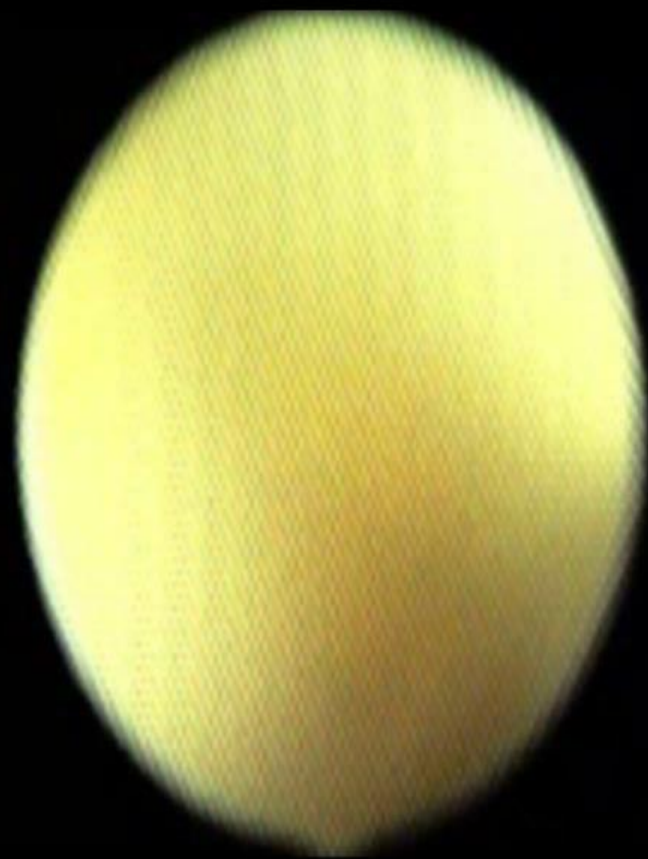


Filling Defect



Case

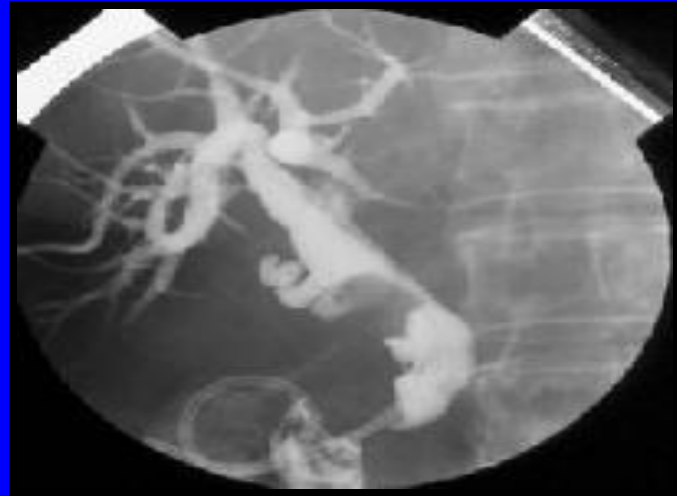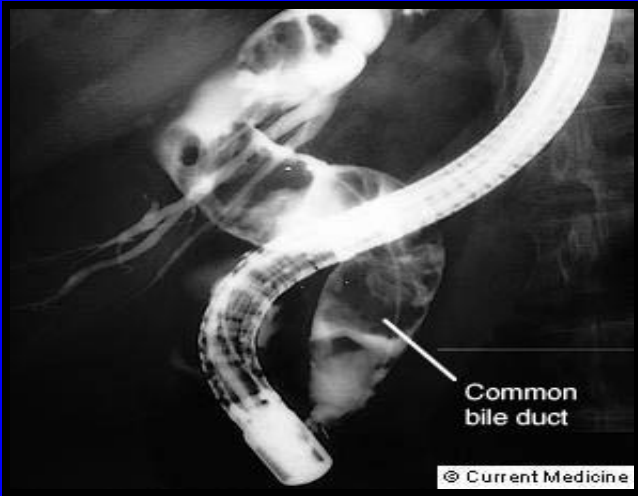

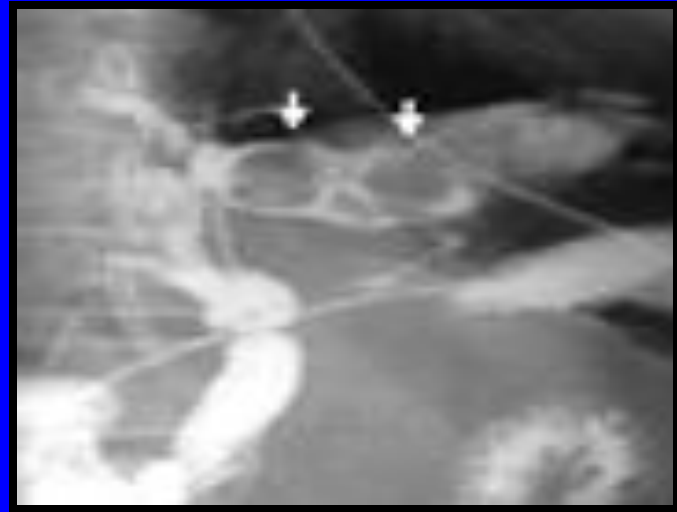
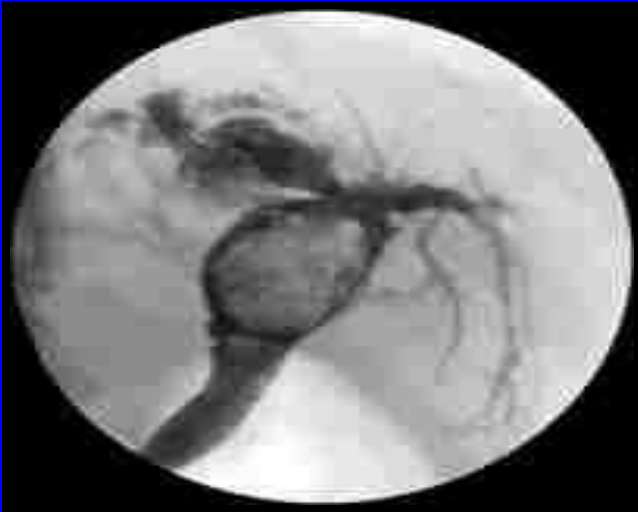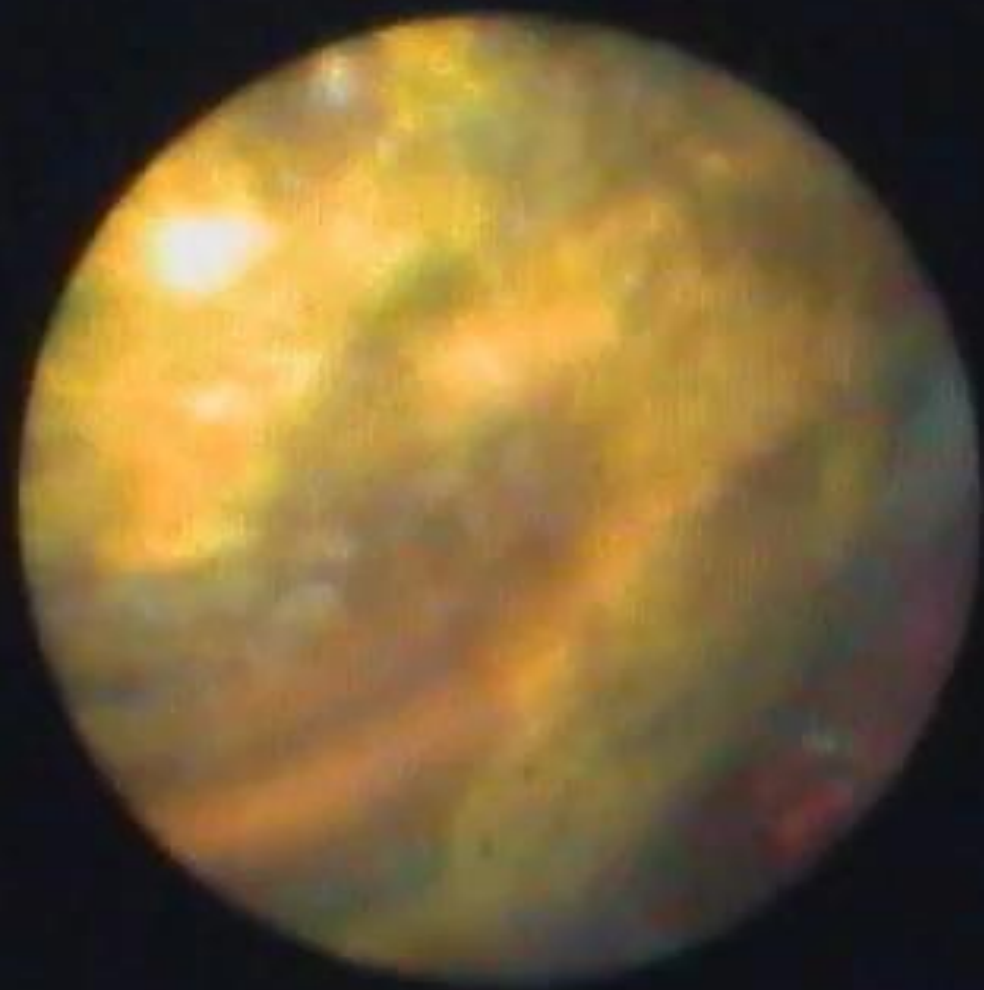


Electrohydraulic Lithotripsy

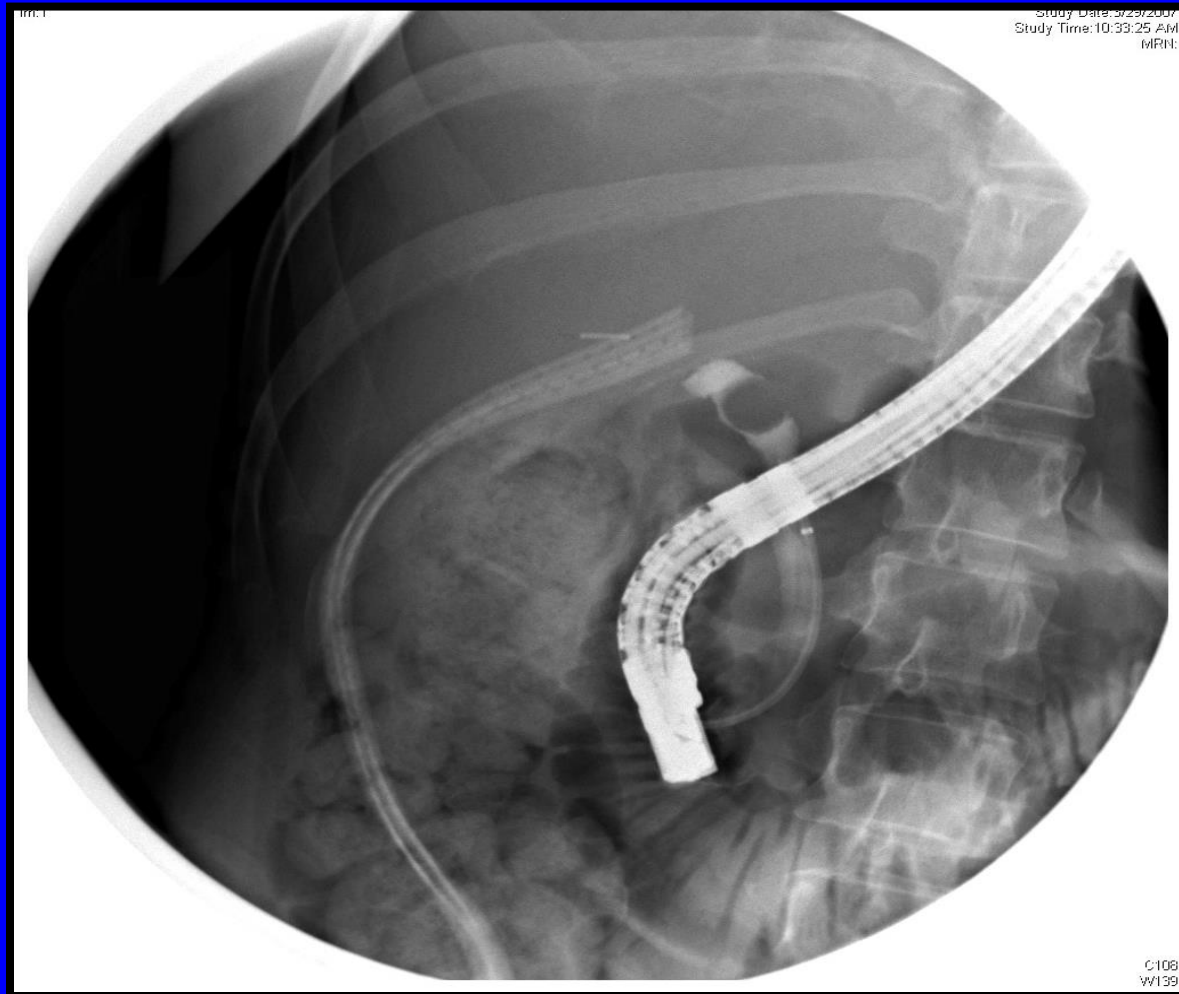

Indications

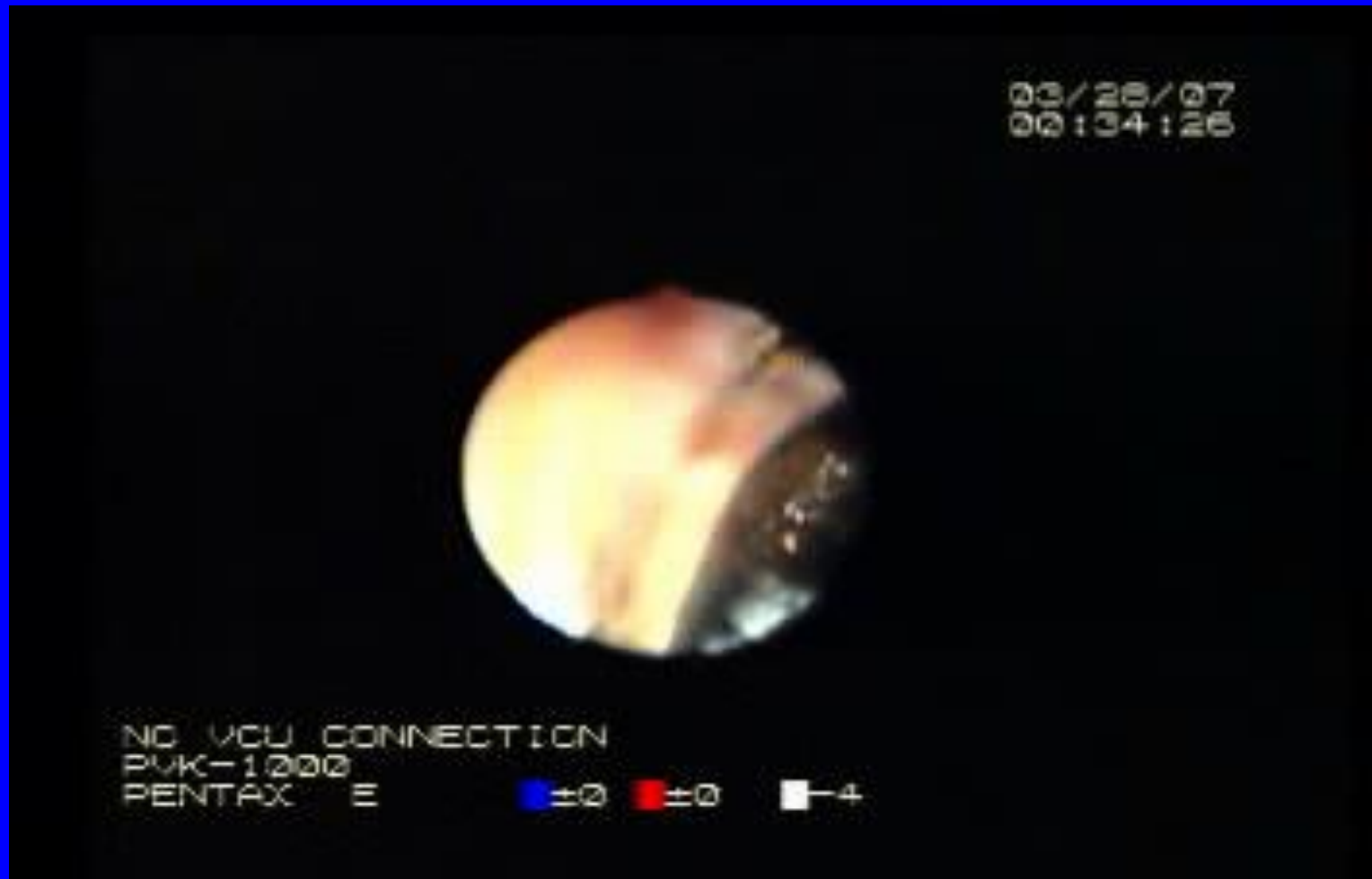



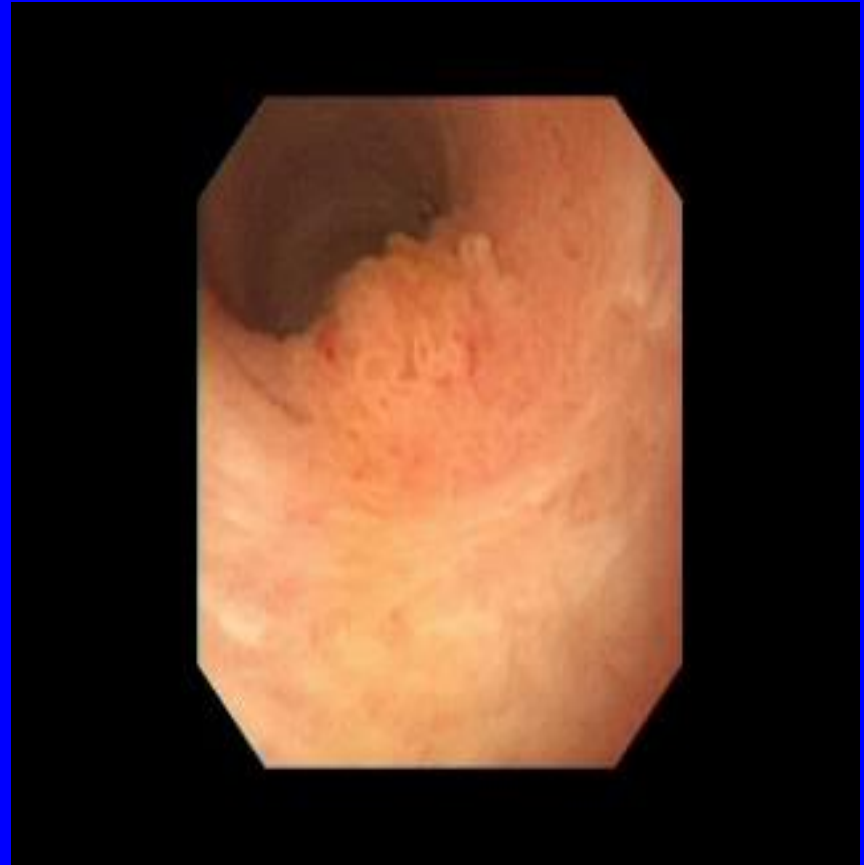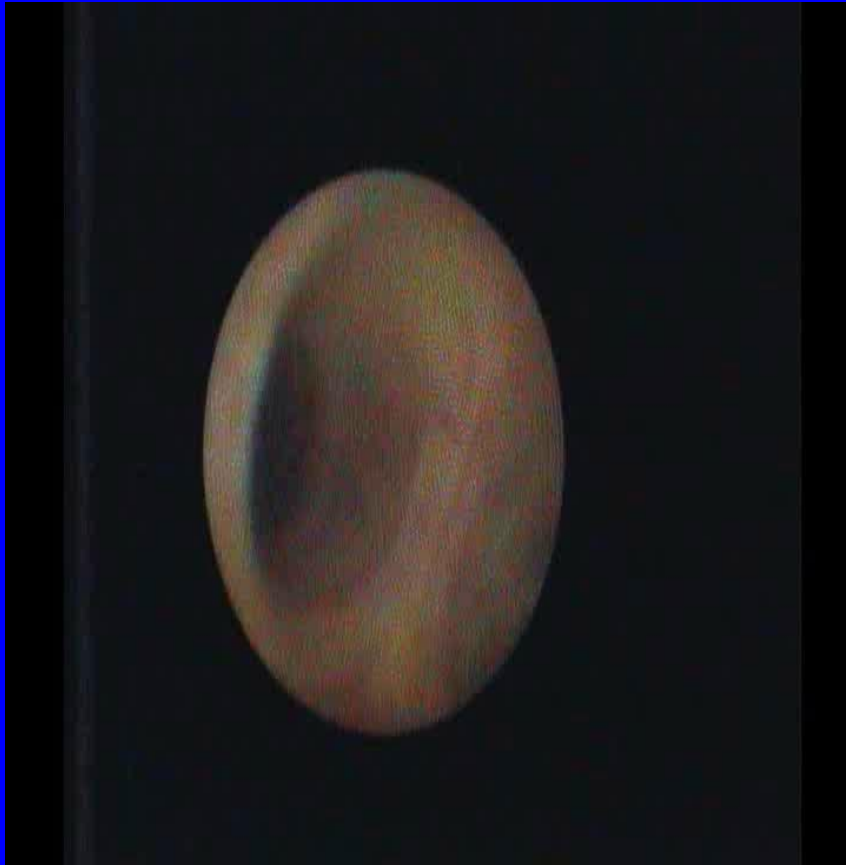
Mirizzi's Syndrome



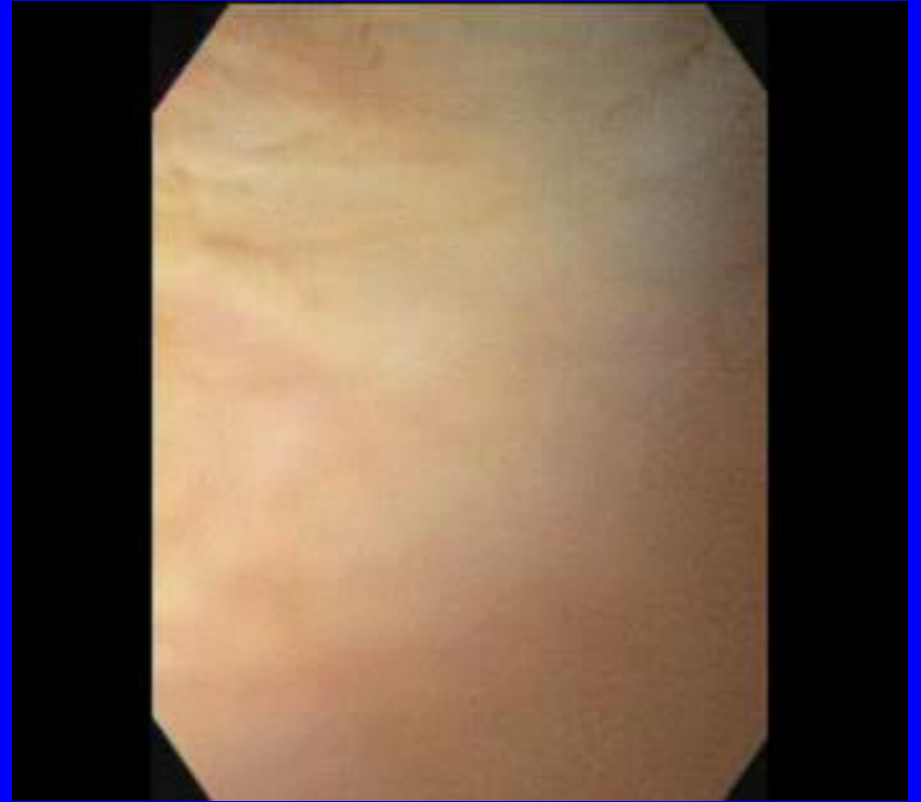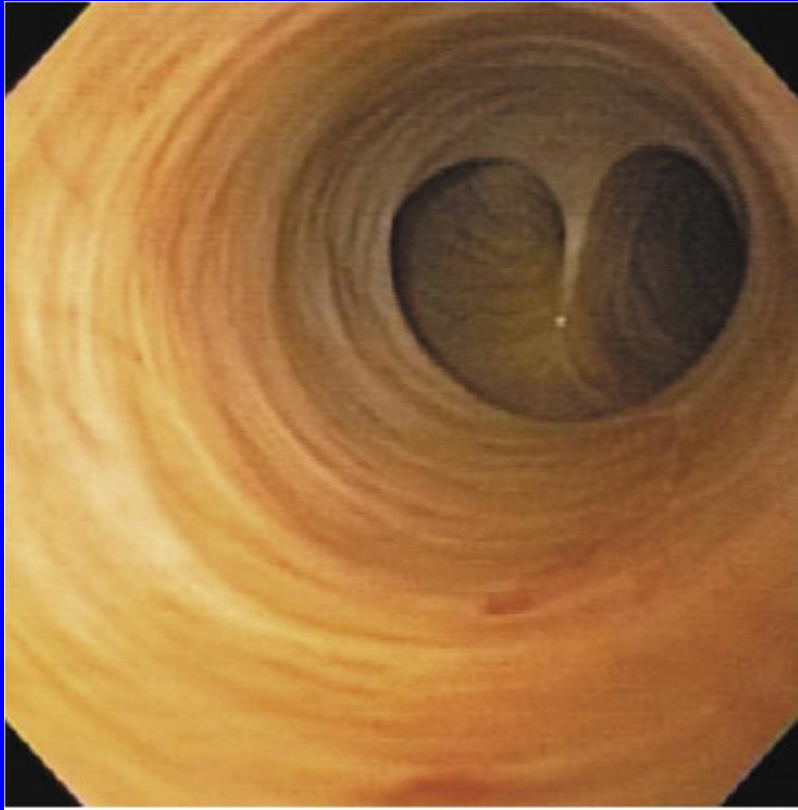
Mirizzi's Syndrome



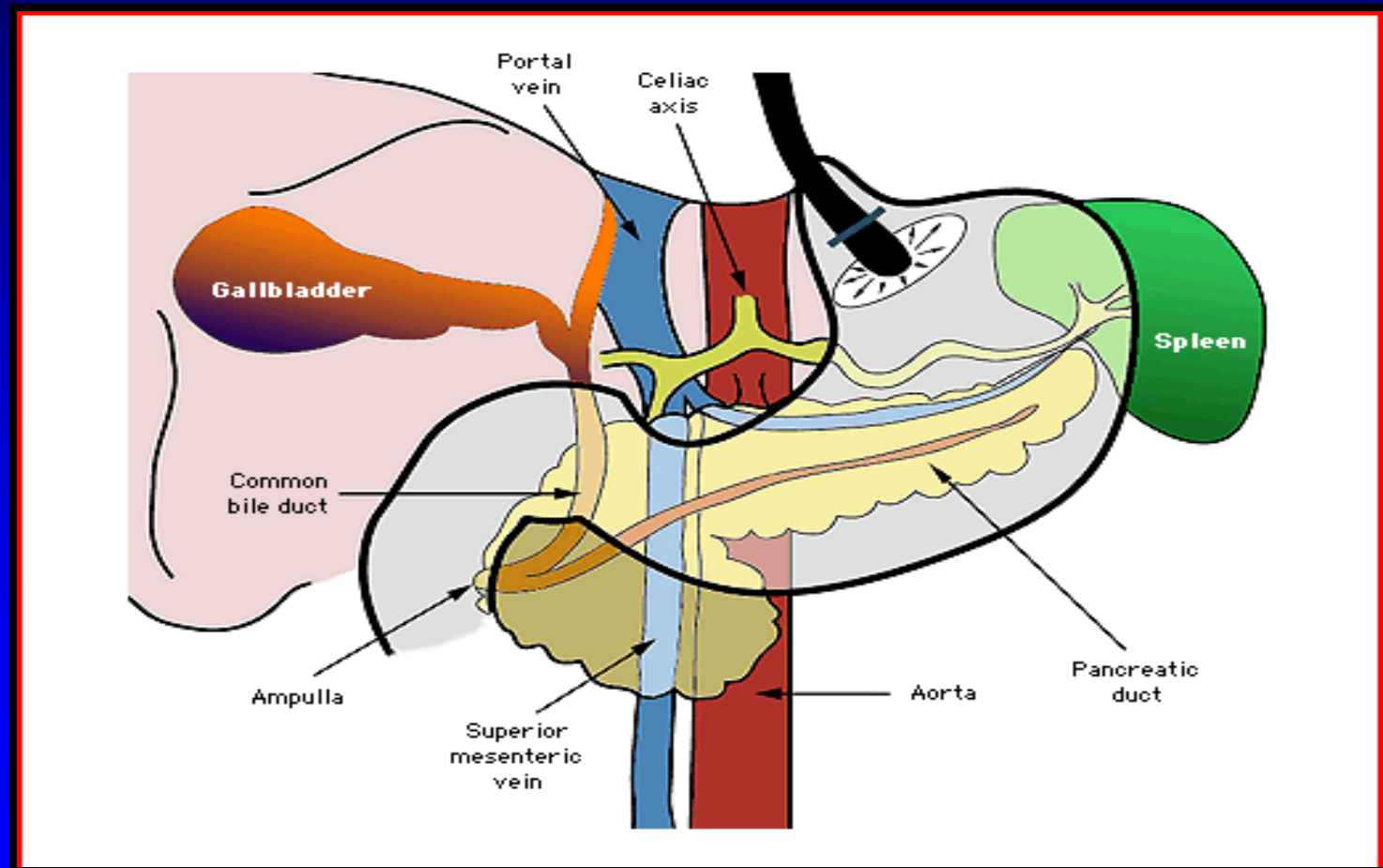
Fiber-optic vs. Video Cholangioscopy



Video Cholangioscopy



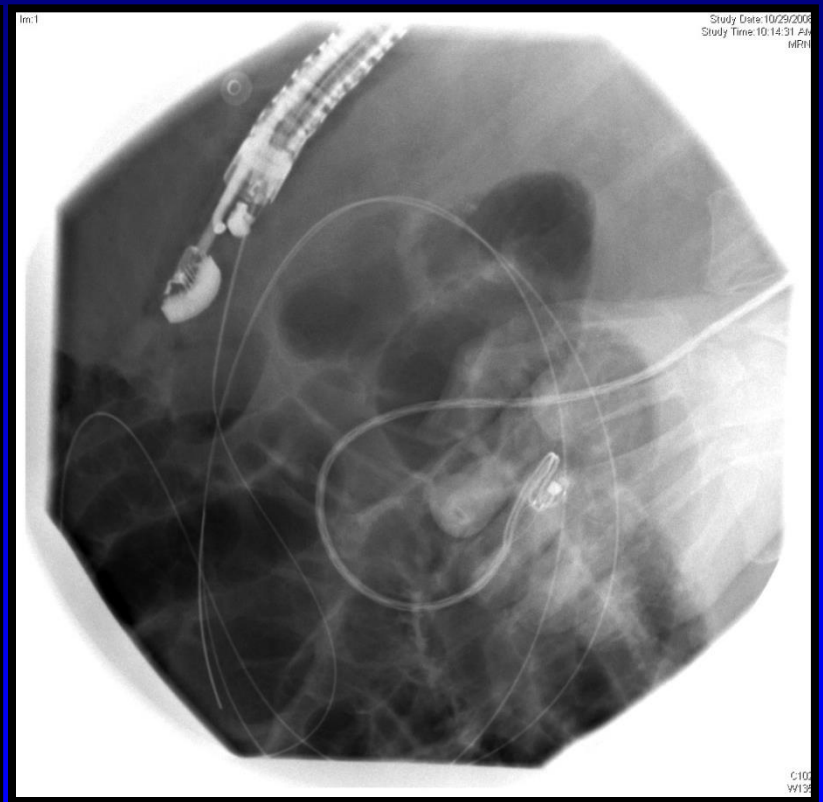
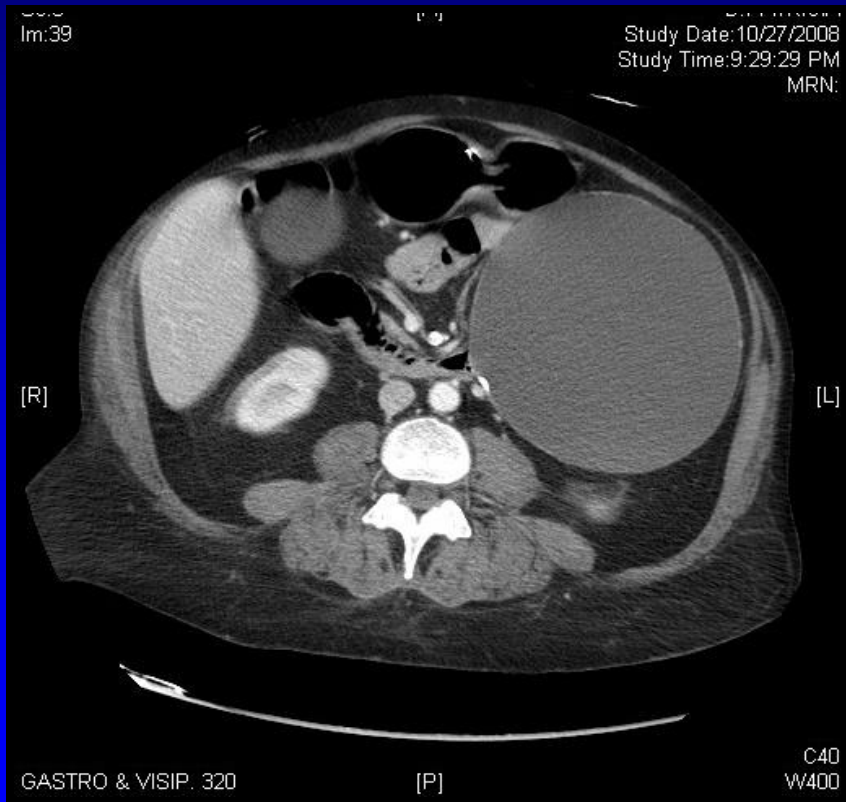
Normal Pancreaticobiliary Anatomy



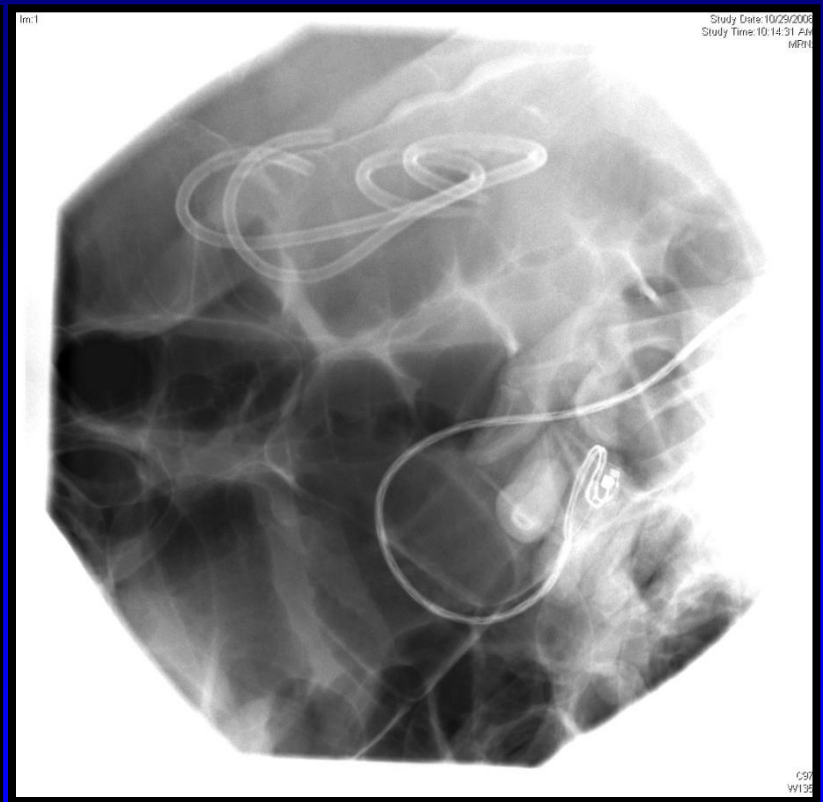
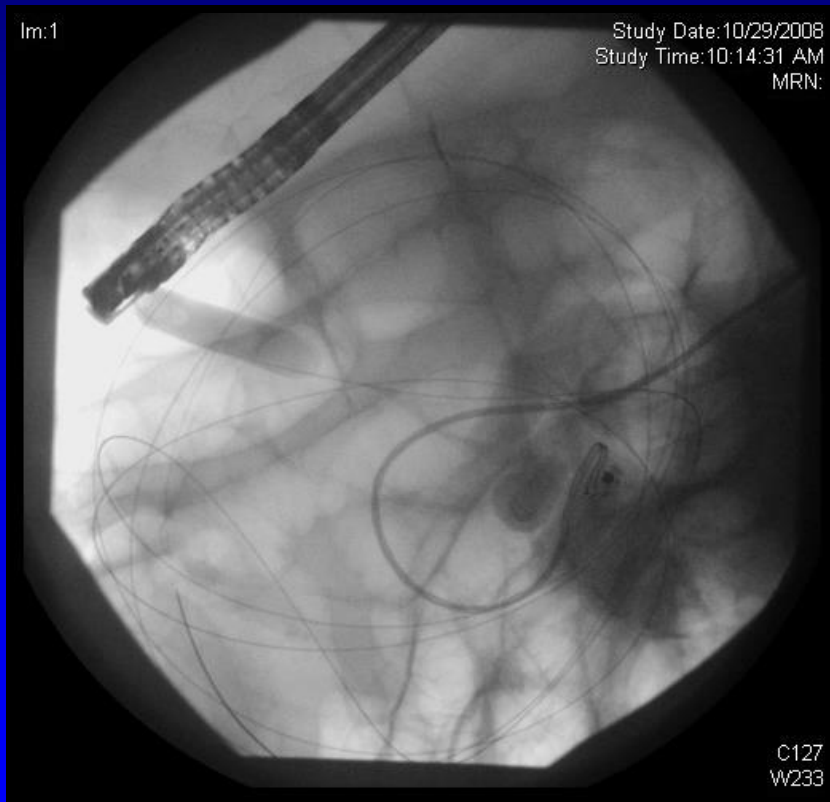EUS-guided Pseudocyst Drainage

- Creation of a fistula between the pseudocyst and the lumen of the stomach or duodenum
- EUS can be helpful in selecting the most favorable puncture site

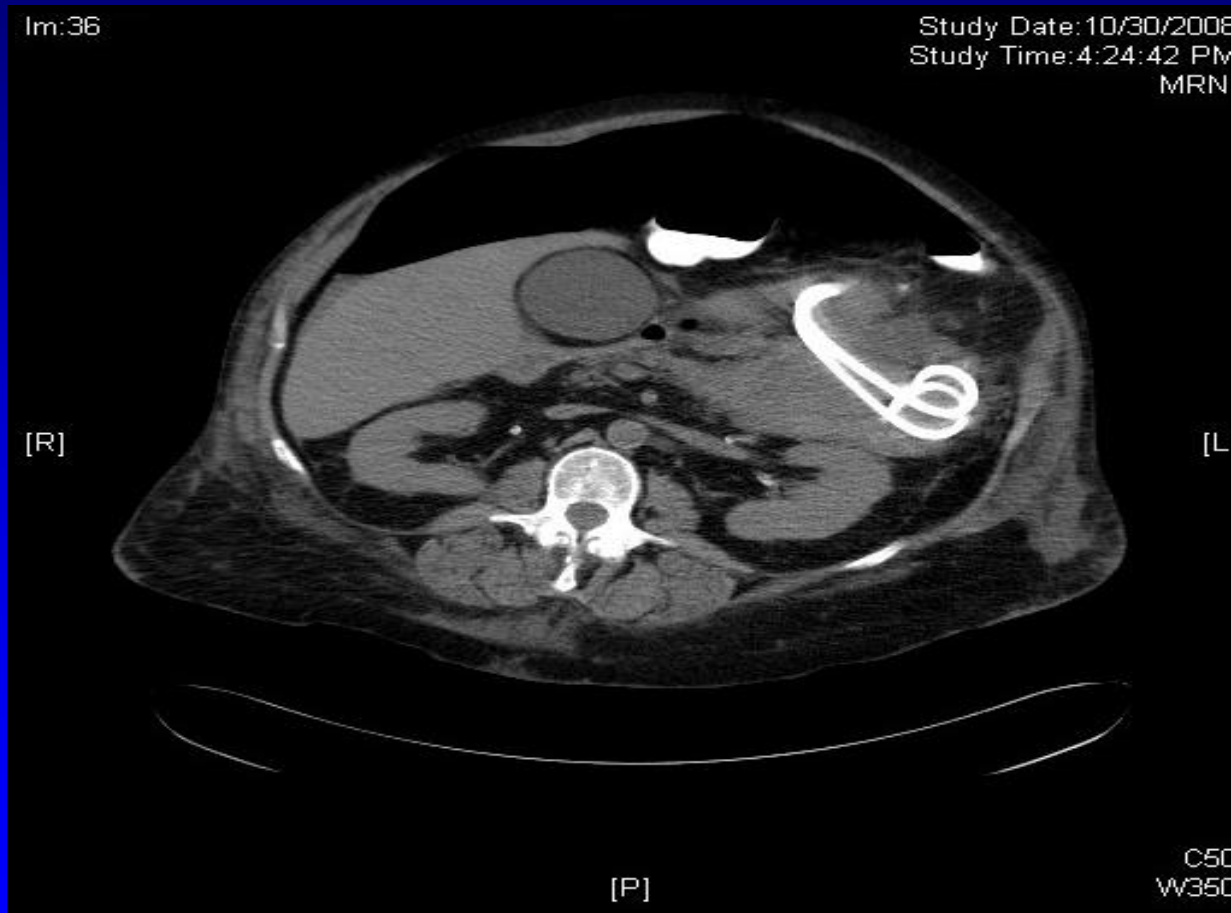
Cyst-gastrostomy

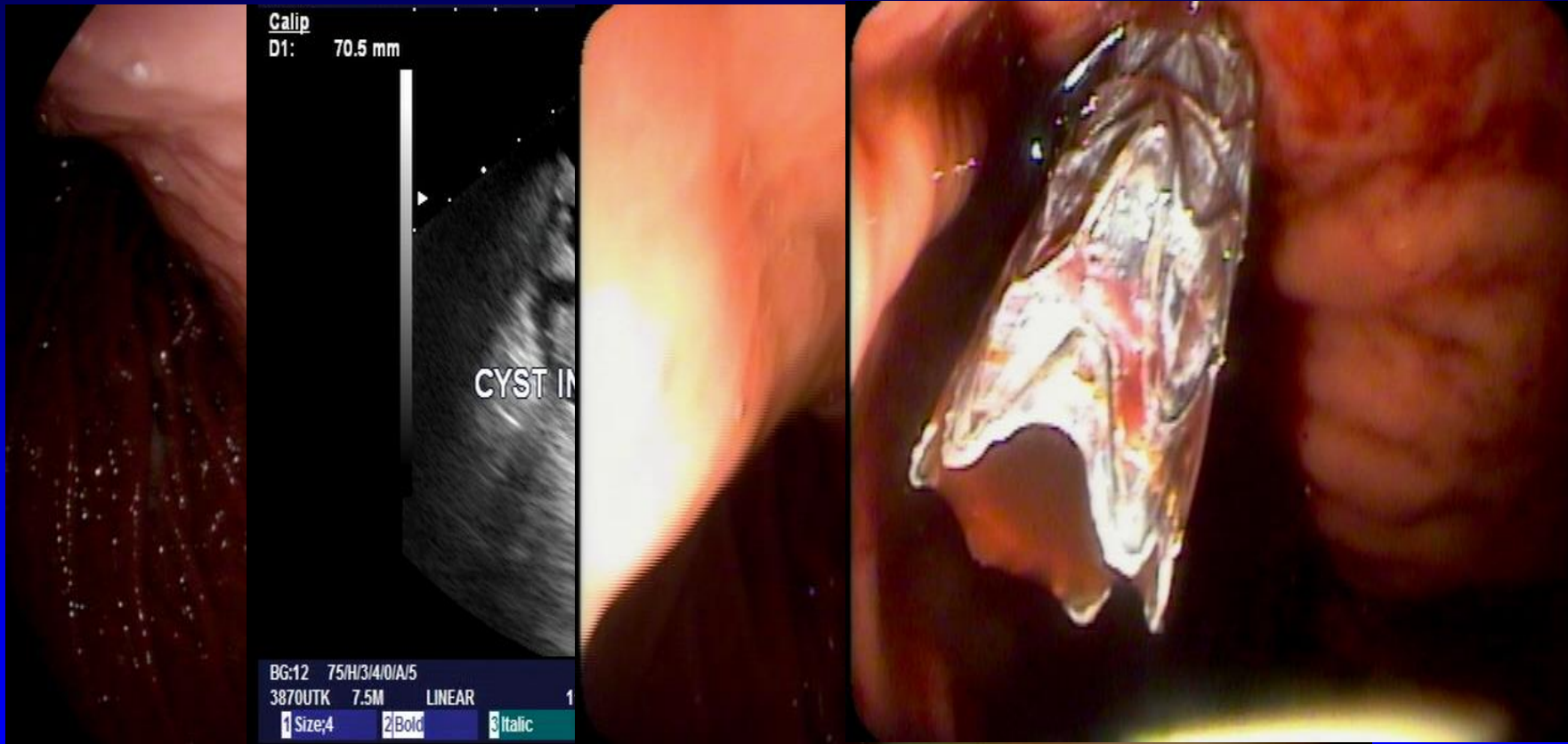


Cyst-gastrostomy



Post-Cystgastrostomy





Galip

D1: 70.5 mm

CYST IN

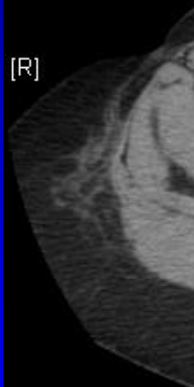
BG:12 75/H/3/4/0/A/5
3870UTK 7.5M LINEAR 1

1 Size:4 2 Bold 3 Italic

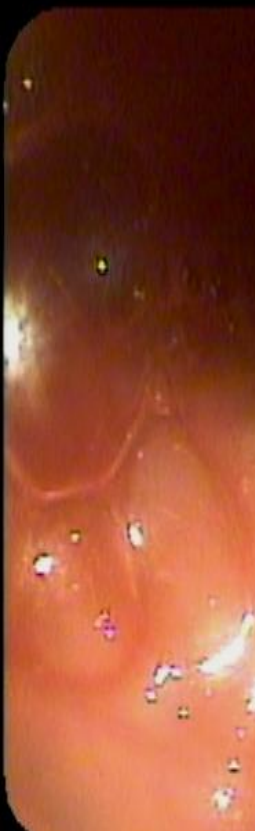
Study Time: 2:00:32 PM
MRN:

HITACHI
FR:35

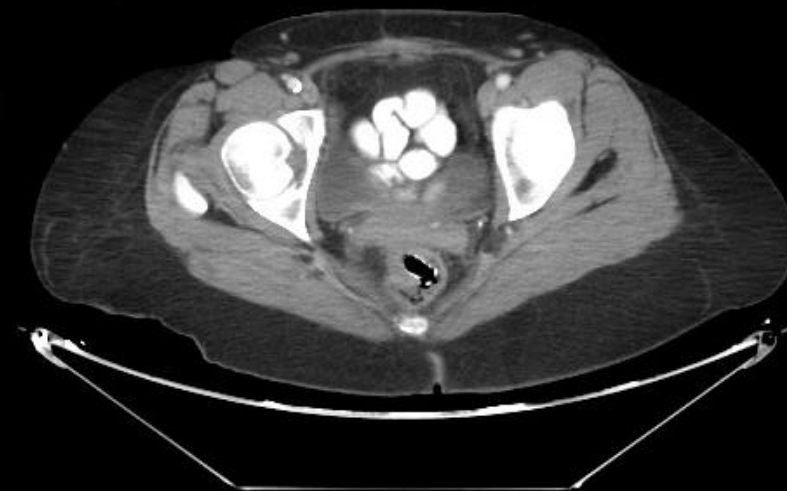[R]



BG:12 65/+3/4/0/A/5
3870UTK 7.5M Endc



[R]




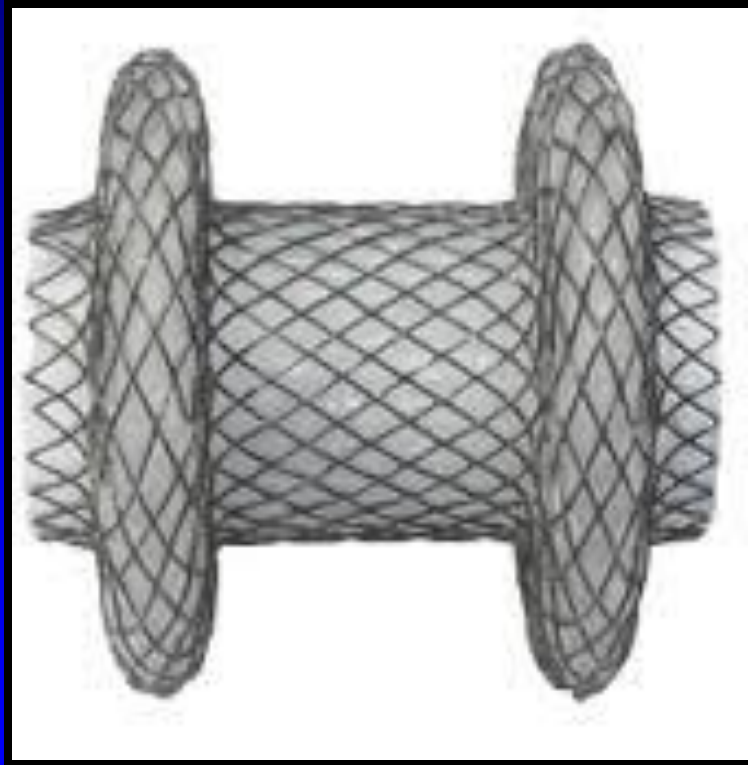
[L]

GASTRO & ISOVUE 300


[P]

C40
W400


Lumen-apposing Metal Stent



Pancreatic Necrosectomy



Peri-rectal Abscess Drainage

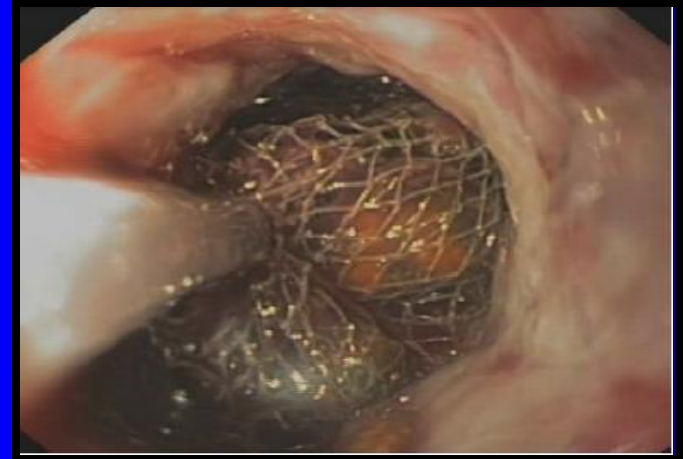
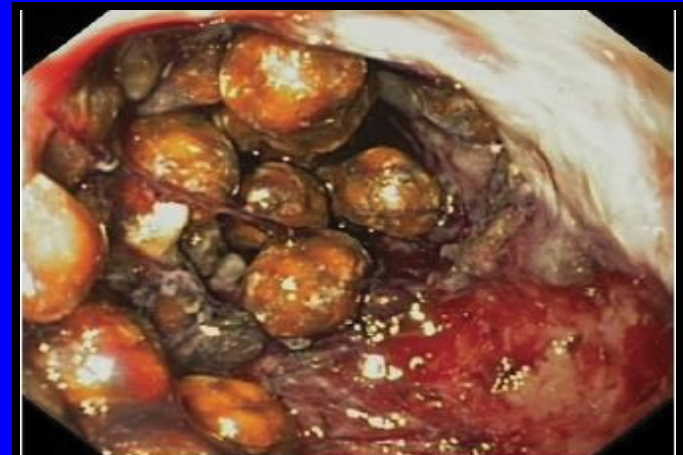
EUS-guided gallbladder drainage with a lumen-apposing metal stent (with video)

Shayan Irani, MD,¹ Todd H. Baron, MD,² Ian S. Grimm, MD,² Mouen A. Khashab, MD³

Seattle, Washington; Charlotte, North Carolina; Baltimore, Maryland, USA

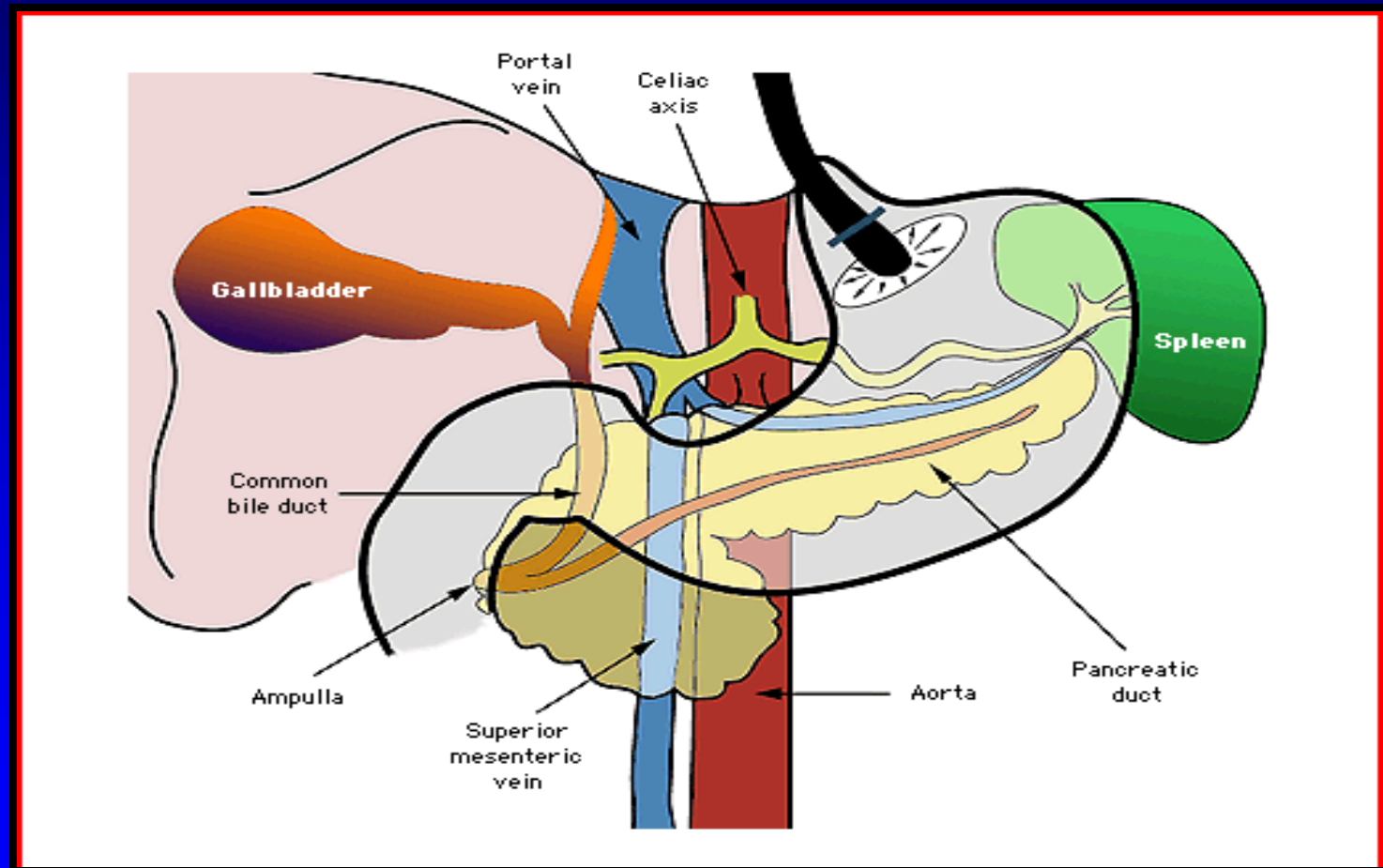
- 15 patients
- Trans-duodenal access: 14/15
- Technical success: 93%
- Median F/U: 160 d
- Adverse event: 1
 - Post-procedural fever



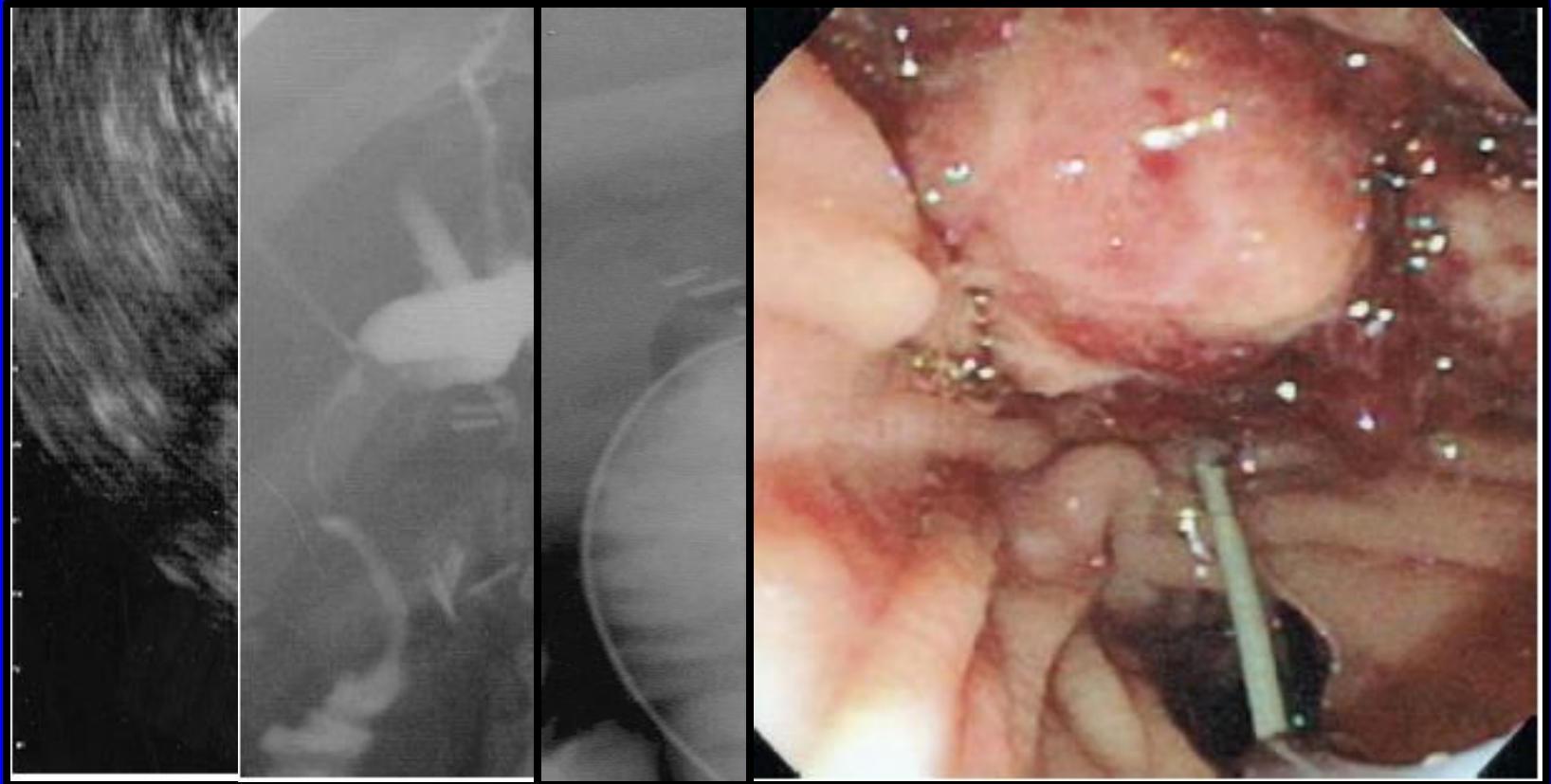
EUS-Guided Biliary Access

- Success rate for ERCP for biliary decompression exceeds 90%
- Potential reasons for failure
 - Prior surgery
 - Peri-ampullary diverticulum
 - Tumor infiltration
- Options: Percutaneous vs. surgical drainage

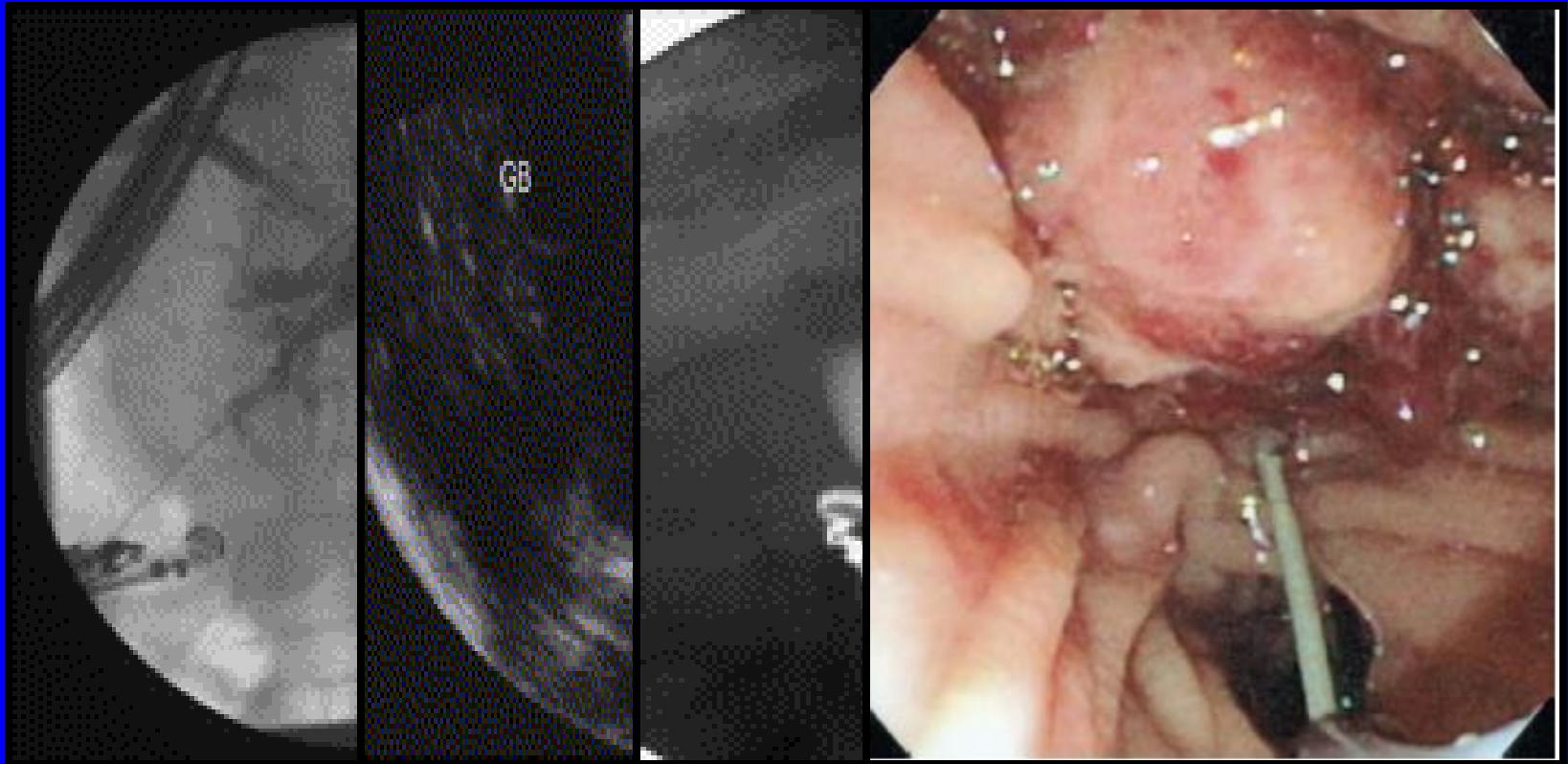
Normal Pancreaticobiliary Anatomy



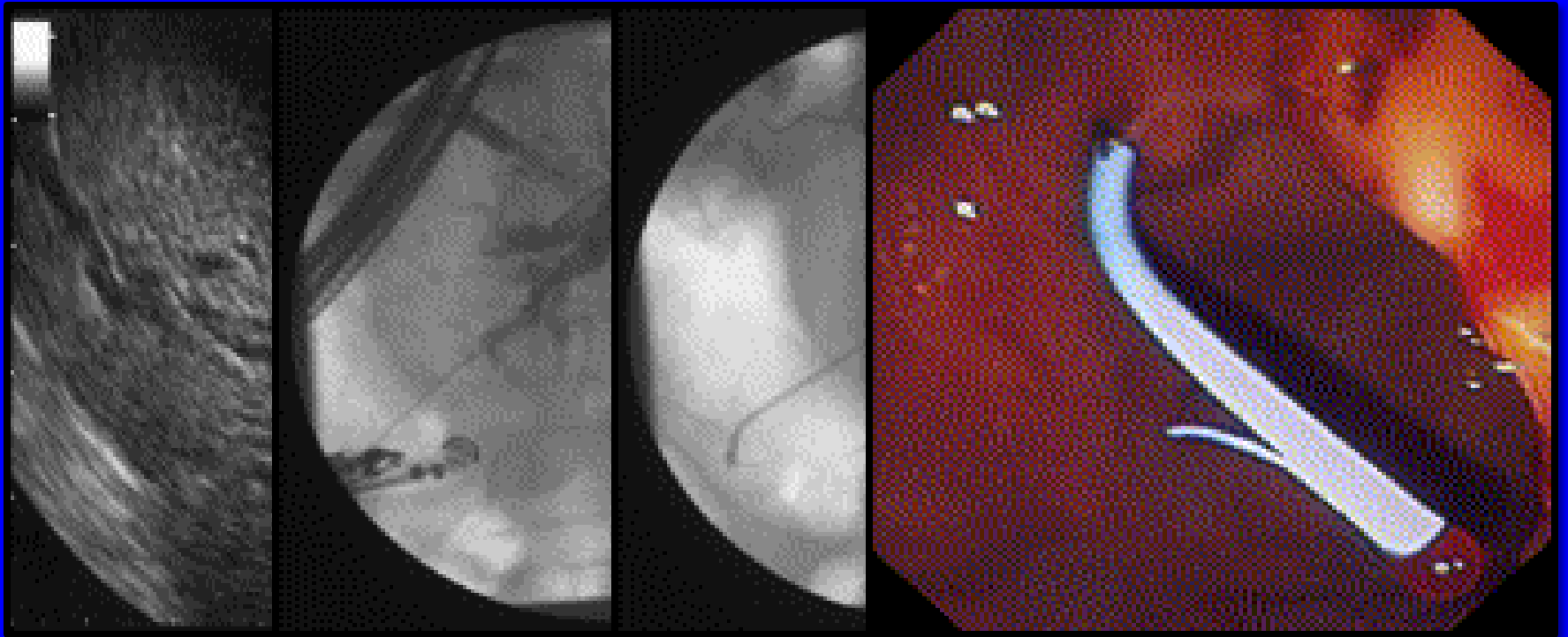
EUS-guided Rendezvous ERCP



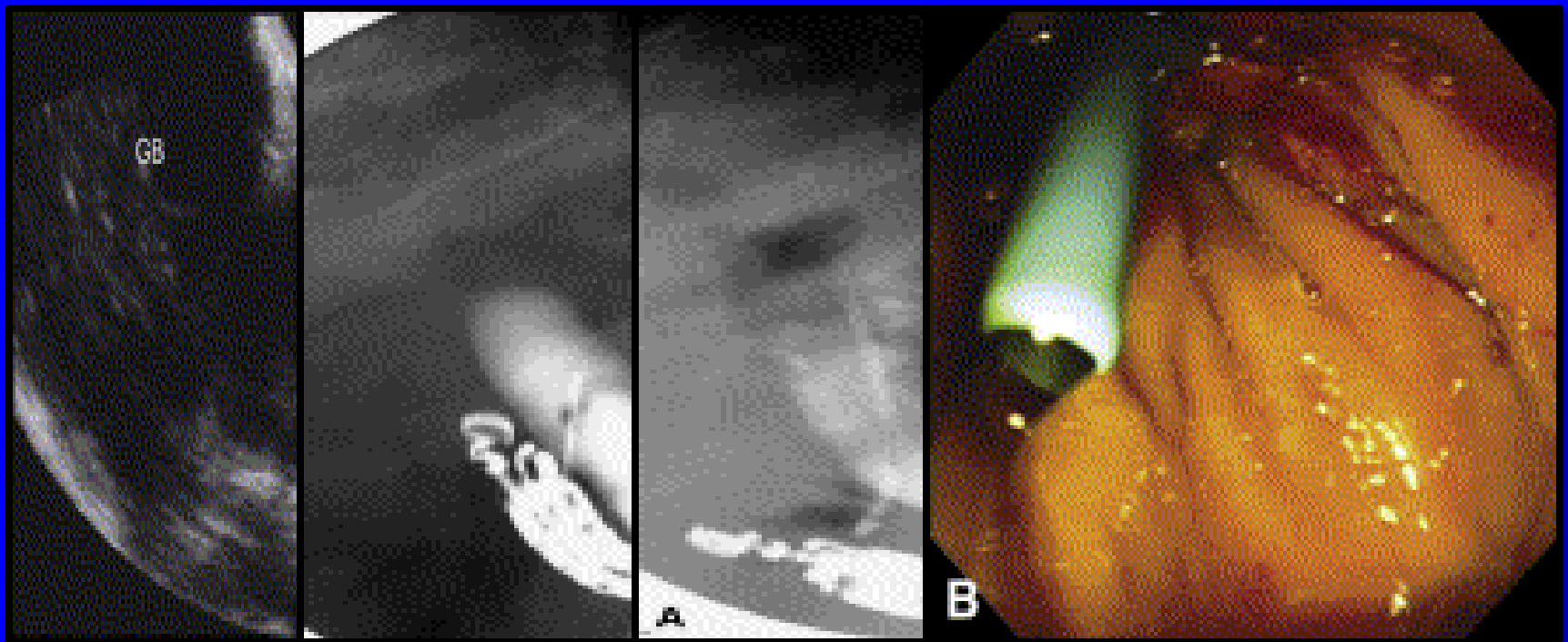
Intrahepatic vs. extrahepatic approach



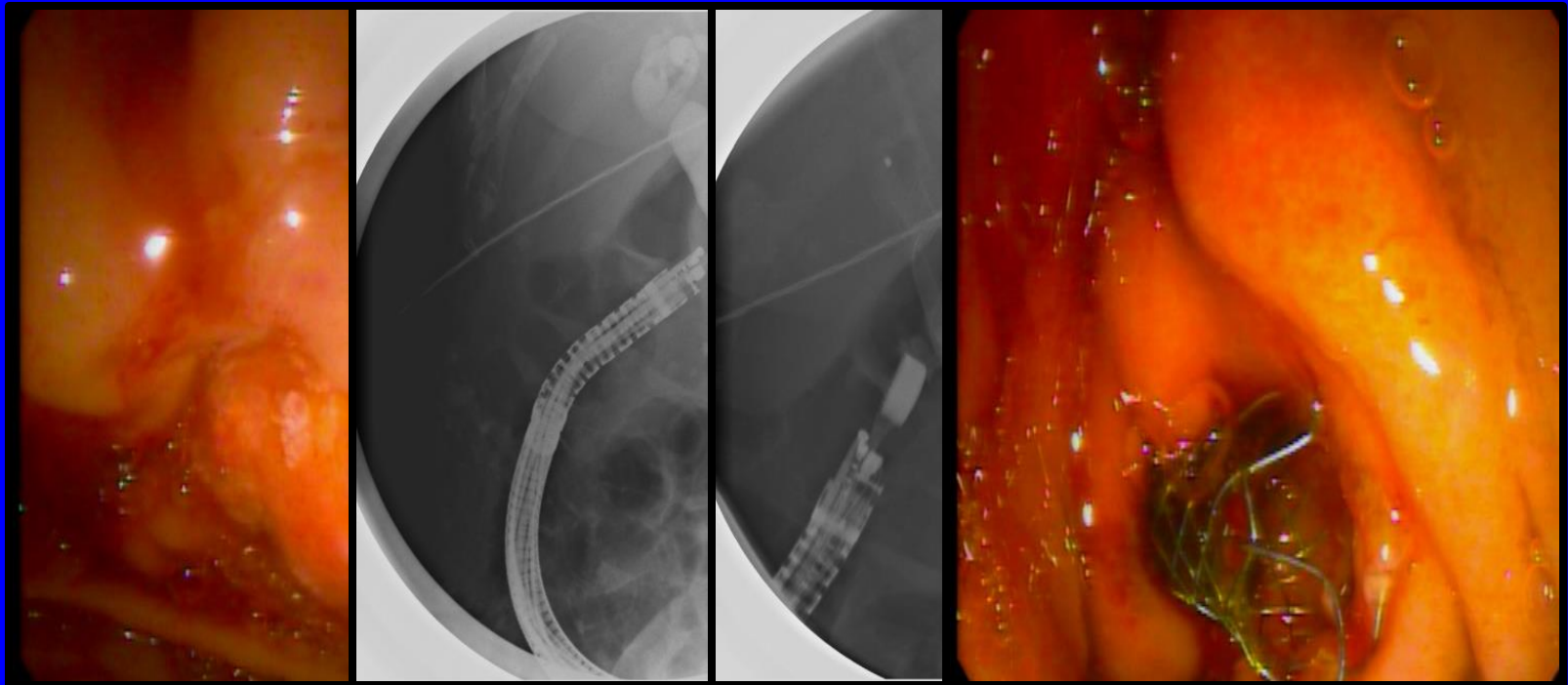
Hepaticogastrostomy




Choledochoduodenostomy



Choledochoduodenostomy



Choledochoduodenostomy



Objectives

- Video cholangioscopy
- EUS-guided pseudocyst drainage and necrosectomy
- EUS-guided biliary access

Thank you for your attention