

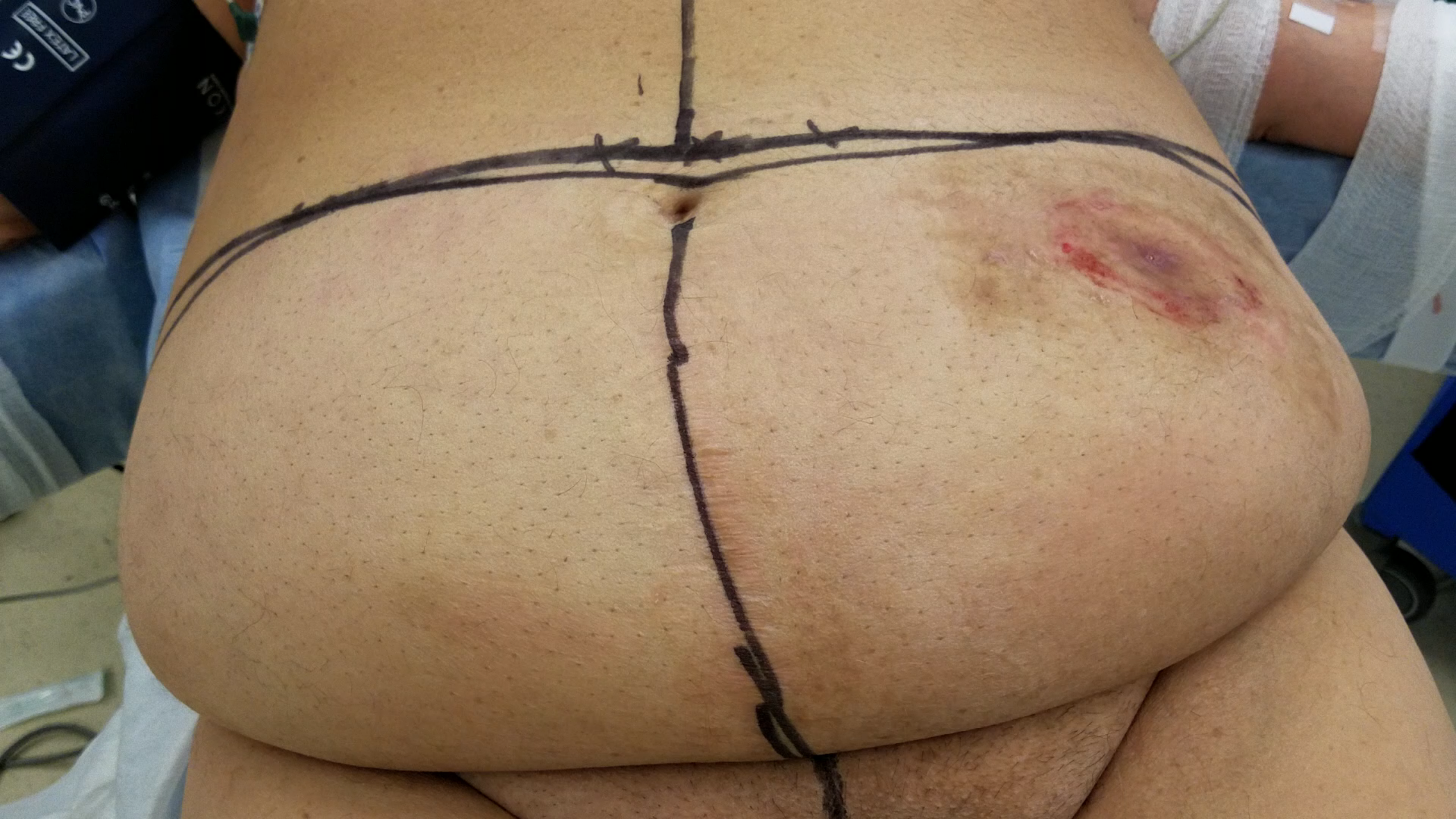Obesity and Hernia Case

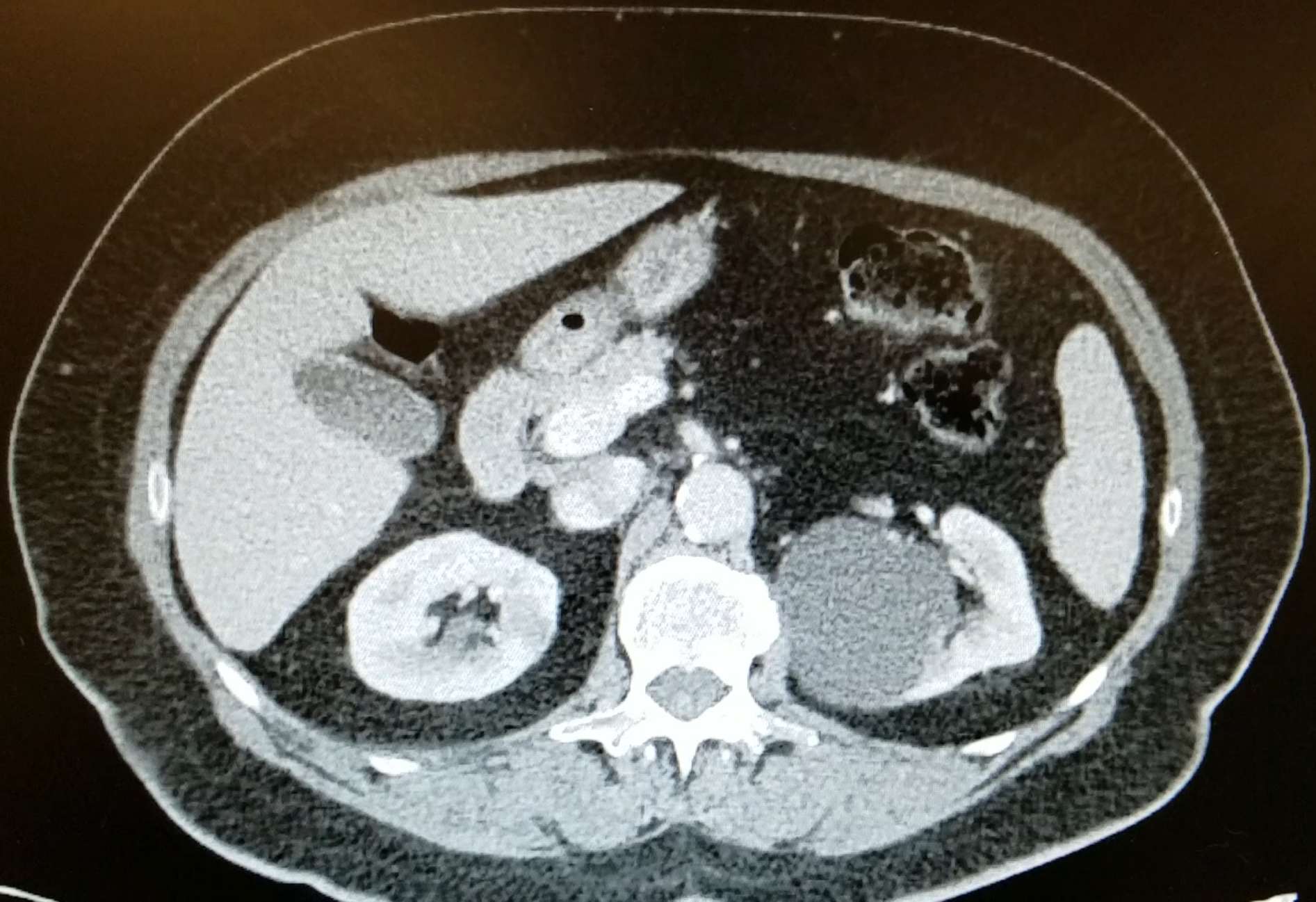
Brian Jacob, MD

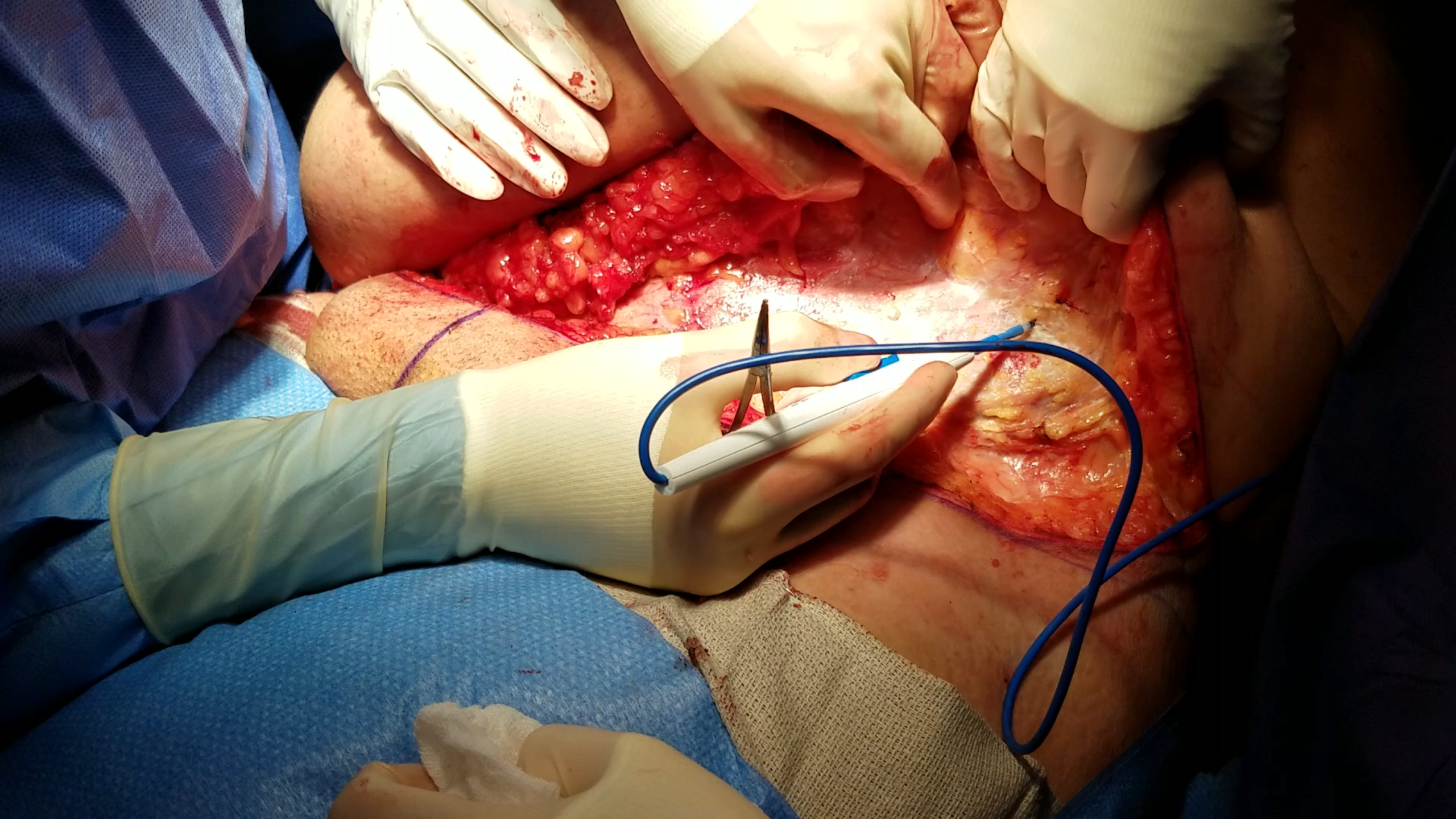
New York City

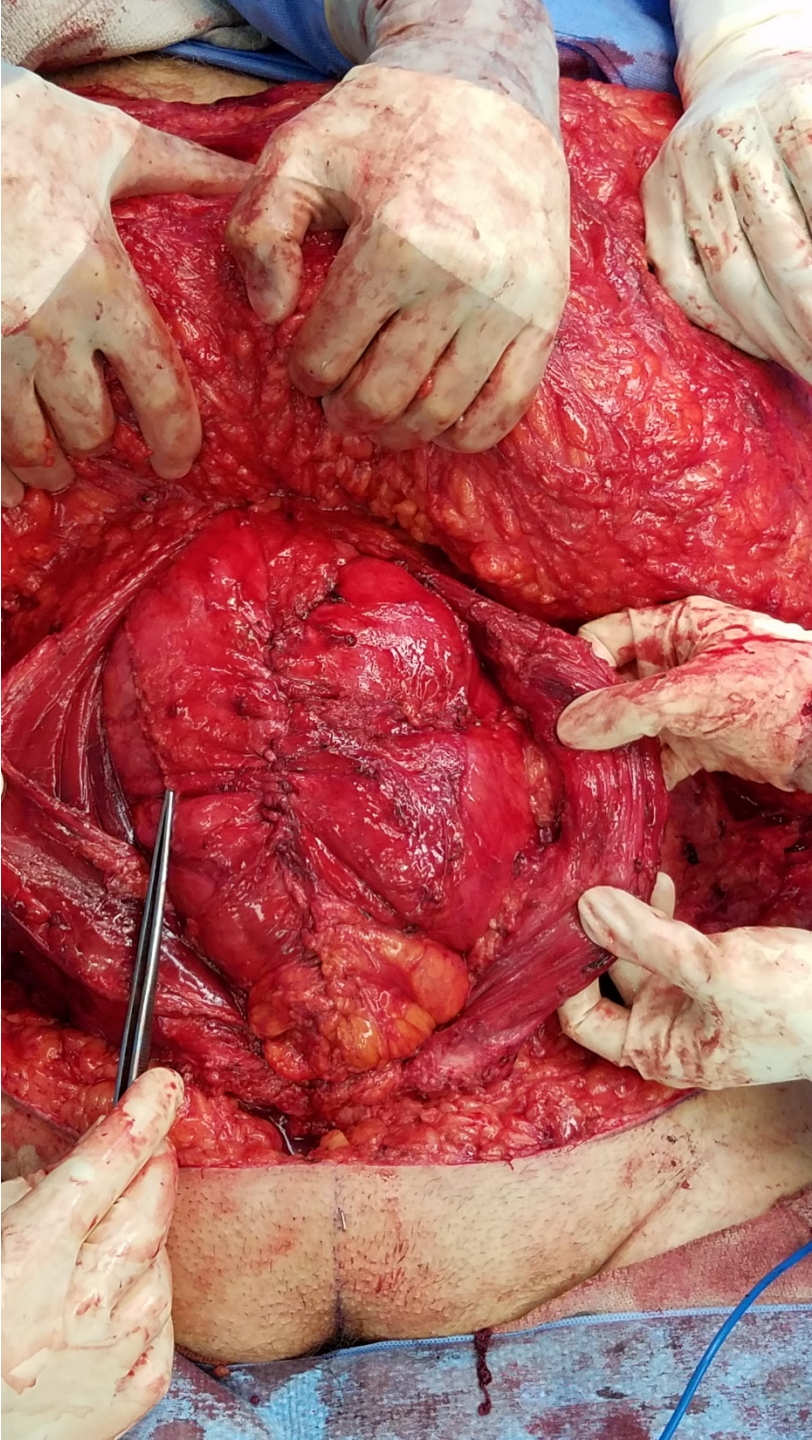
When skin needs to come off

- 69 male
 - Bmi 42 down to 34
 - Perforated colon cancer
 - Hartmann, chemotherapy
 - Reversed
 - Incisional and old stoma site hernia
- PMH
 - Dvt
 - Cad









- s/p bilateral TAR
- Posterior fascia closed

